

## **Pathomorphological changes in the tissues of chickens, experimentally infected with biting lice (Insecta: *Phthiraptera*)**

**Petyo Nedelchev Prelezov<sup>1\*</sup>, Nelly Ivanova Groseva<sup>2</sup>,  
and Dimitrina Ivanova Goundasheva<sup>2</sup>**

<sup>1</sup>*Department of Veterinary Microbiology, Infectious and Parasitic Diseases, Faculty of Veterinary Medicine, Trakia University, Stara Zagora, Bulgaria*

<sup>2</sup>*Department of General and Clinical Pathology, Faculty of Veterinary Medicine, Trakia University, Stara Zagora, Bulgaria*

---

**PRELEZOV, P. N., N. I. GROSEVA, D. I. GOUNDASHEVA: Pathomorphological changes in the tissues of chickens, experimentally infected with biting lice (Insecta: *Phthiraptera*). Vet. arhiv 76, 207-215, 2006.**

### **ABSTRACT**

A study into the death rate and pathomorphological changes in the tissues of chickens experimentally infected with biting lice from the species *Eomenacanthus stramineus* Nitzsch (1818), *Menacanthus cornutus* Schömmmer (1913), *Menopon gallinae* L. (1758) and *Goniocotes gallinae* DeGeer (1778) is presented. Five of 20 infected birds died (25% death rate). Following necropsy of dead birds and after histological investigation of skin, muscle, spleen, liver, lungs and kidney specimens, multiple wounds and haemorrhages were macroscopically observed on skin surface, while histologically in all cutaneous layers, as well as in the other studies, tissue hyperaemia, haemorrhages, haemosiderosis, pseudoeosinophilic and hystiocytic infiltration were present. Inflammation of the small intestines was also noticed. The evidenced changes were of both local and systemic character. Local lesions were due to the direct aggression of *Mallophaga*. The systemic changes were manifestations of the sensitization and intoxication that occurred in the avian organism following the biting lice infestation.

**Key words:** *Phthiraptera*, *Mallophaga*, chickens, pathomorphology, hyperaemia, haemosiderosis

---

### **Introduction**

Although known as biting lice, the representatives of *Mallophaga* use a broad spectrum of substrates as a food source. After studying the content of the alimentary tract of those insects, WATERSON (1926) proved that apart from particles of feathers and epidermal cells there were also quartz granules, seed flakes, fungal spores and blood. The haematophagia of *Mallophaga* from the *Amblycera* suborder was established as early as in 1778 by DE

\* Contact address:

Petyo Nedelchev Prelezov, Assistant Professor, Trakia University, Faculty of Veterinary Medicine, Department of Veterinary Microbiology, Infectious and Parasitic Diseases, 6000 Stara Zagora, Bulgaria, Phone: +359 42 699 590, E-mail: pprelesov@abv.bg

GEER and later confirmed by DERYLO (1974), DERYLO and GOGACZ (1974), AGARWAL et al. (1983). During blood ingestion biting lice are probably in very close contact with the host organism, which is accompanied by systemic as well as local reactions. For instance, DUBININ (1947) has observed cutaneous wounds caused by insects belonging to genus *Piagetiella* in pelicans. Similar changes have been reported by CLAYTON and TOMPKINS (1995) in mallophagosis of rock doves. In 1974 DERYLO reported that apart from the cutaneous wounds and haemorrhages in chickens infected by *Menopon gallinae* L. (1758), secondary changes such as erythema, inflammation and eruptions were also observed. Furthermore, he observed a strong pruritus. Enzootic cutaneous lesions in *Mallophaga*-infected finches were reported by McCLURE (1989). Several authors have published data about allergic reactions in animals infected by biting lice (MOCK, 1977; HALLIGAN and JOHNSTONE, 1992; PFEFFER et al., 1994; JAMES and MOON, 1998). FABIYI (1986) observed lethargy and delayed growth in hens and turkeys with mallophagosis.

The aforementioned various local and systemic functional troubles in mammals and birds with mallophagosis raise the question as to whether they are accompanied by pathohistological changes in their tissues. The bibliographic information on that subject is scarce.

Thus, the aim of our study was to determine the pathomorphological changes in the skin, musculature, spleen, liver, lungs, kidneys and small intestines in chickens experimentally infected with biting lice.

### **Materials and methods**

Forty two-month-old chickens of the Yaffa egg-laying breed were used. They were housed in two premises (area 6 m<sup>2</sup> and height 3 m) disinfected with warm 2% NaOH solution prior to the experiment. The birds were divided into two groups: experimental (n = 20) and control (n = 20).

After a thorough clinical and laboratory examination it was established that the chickens were free of infectious, parasitic or deficiency diseases. No invasion with endo- and ectoparasites was observed. The birds were fed with combined forage for growing chickens containing coccidiostatics, vitamins and trace elements in a daily amount of 0.1 kg per each chicken.

As the aim of the experiment was to provoke an infestation with *Mallophaga*, close to the natural route of infection, we used 4 donor hens with evidence of strong infestation with the following species: *Eomenacanthus stramineus* Nitzsch (1818), *Menacanthus cornutus* Schömmer (1913), *Menopon gallinae* L. (1758) and *Goniocotes gallinae* DeGeer (1778).

After a one-week adaptation period the donors were introduced into the room with the experimental chickens. For closer contact, each day one of the donors was put together with 3-4 experimental birds in a 150/70/80 cm cage for 30 min. The intensity of invasion

in experimental birds was determined via counting the biting lice on eleven 8 cm fields with round shape (head, neck, breast, abdomen, cloaca, back, legs, wings) of the body of each bird.

The experimental period spanned a period of 12 months (May to April).

The number of biting lice in dead experimental chickens was established via rubbing the feathers with a cotton swab soaked in diethyl ether and placing the bird in a tightly closed polyethylene bag for 15 min immediately after the lethal issue. The body was then removed from the bag and the feathers were vigorously rubbed over a sheet of white paper. All biting lice on the sheet and within the polyethylene bag were counted.

All dead birds were necropsied and specimens from the skin in the region of the cloaca, the sternal muscles, spleen, liver, lungs, kidneys and small intestines were collected for pathohistological study. After a 48-hour stay in 10% neutral formaldehyde the specimens were embedded in paraffin, cut with a microtome (Reichert, Austria) and 5 µm cross-sections were stained with haematoxylin-eosin using the routine technique.

Inspection of preparations and photography was performed with an Axioskop® microscope (Zeiss).

## Results

Changes in the intensity of invasion in chickens infected with *Mallophaga*.

Thirty days after the introduction of donors in the premises housing experimental chickens, all were infected with all four *Mallophaga* species. The intensity of invasion in individual birds ranged from 28 to 148 biting lice.

During the experimental period, five birds from the experimental group died (25%). The results of the bacteriological analysis of skin, muscles and viscera in all chickens were negative for pathogenic micro-ora. All birds from the control group survived.

Data for the intensity of invasion in the dead experimental chickens are shown in Table 1. The total number of biting lice found on dead birds, aged between 4 and 14 months, was between 847 and 1265 individuals, with a predominance of the *Menopon gallinae* species.

Table 1. Intensity of invasion in dead chickens, experimentally infected with biting lice of various species.

Bird N°	Age (months)	<i>E. stramineus</i>	<i>M. cornutus</i>	<i>M. gallinae</i>	<i>G. gallinae</i>	Total N°
1	4	88	131	790	256	1265
2	5	66	133	490	158	847
3	12	75	69	648	380	1172
4	13	102	95	770	190	1157
5	14	90	75	580	250	995

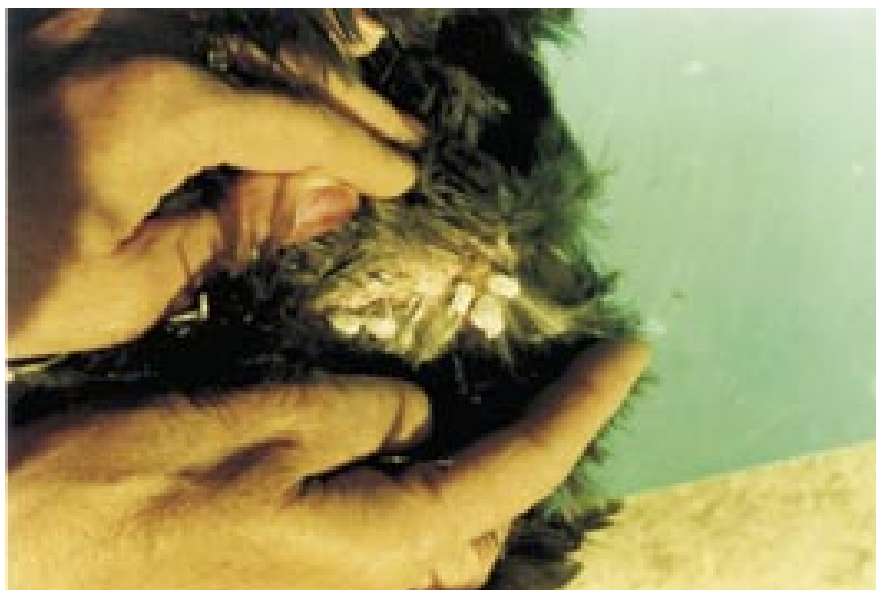

Fig. 1. Conglomerates of *Eomenacanthus stramineus* eggs at the base of feathers around the cloaca of a chicken.

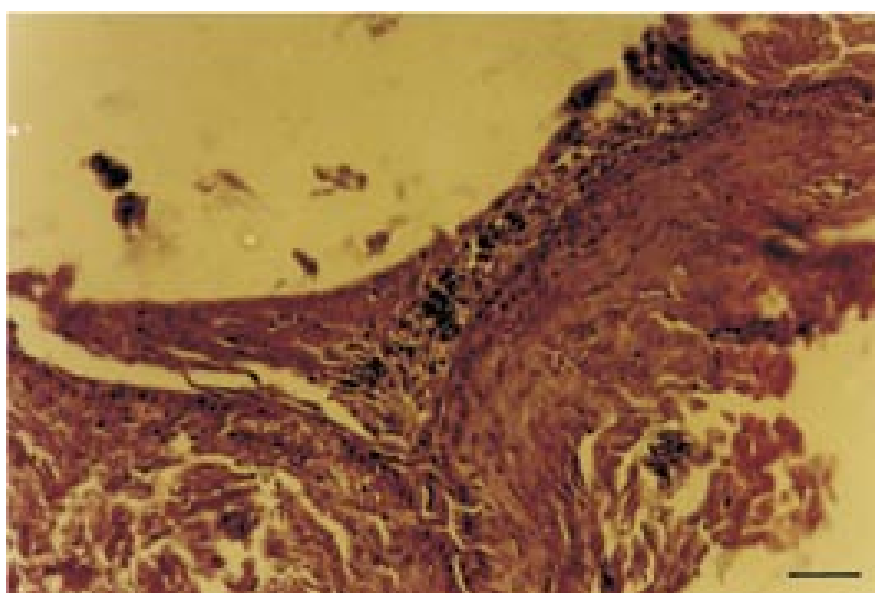


Fig. 2. Histopathological changes in the skin of a chicken, experimentally infected with biting lice. Scale bar = 25  $\mu$ m.

*Pathoanatomical changes in the tissues of chickens infected with Mallophaga.* Following necropsy a body cachexia was observed. The comb, caruncles and the visible mucosae were anaemic. There were shapeless areas with a lack of feathers on the skin in the region of the cloaca, the abdomen and the breast with petechias, superficial wounds and brownish scabs with a size between millet and corn seeds (1-5 mm).

The feathers of the body were ruf ed and those near the cloaca were stained with faeces.

The characteristic oval conglomerates of *Eomenacanthus stramineus* eggs, as well as multiple larvae and imagos of this species, were present at the base of feathers around the cloaca (Fig. 1).

Dissection of the pleuroperitoneal cavity revealed hyperaemia of the liver, spleen and kidneys. Lungs were hyperaemic and oedematous.

*Histopathological changes in the tissues of chickens, infected with Mallophaga.* Through microscopic examination of the skin from the region of the cloaca, massive hyperaemia accompanied by haemorrhages and haemosiderosis was observed. Multiple haemosiderocytes were encountered perivascularly in smaller or bigger groups. Single eosinophilic leukocytes were also observed (Fig. 2).

Within the skeletal muscles there were hyperaemic blood vessels, granular and hyaline dystrophy. In some muscle fibres, myofibril dissociation and a granular appearance of sarcoplasm with mild interstitial oedema were present. In other fibres, the transverse or longitudinal striated pattern had disappeared with homogenization of the content. Many eosinophilic leukocytes were seen in the regions showing granular degeneration.

In the liver, a diffuse hyperaemia and a severe haemosiderosis were established. The capillary endothelium was activated, and was concave towards the lumen. Many Kupfer's cells were seen in the lumen of capillaries. In some places a granular or fatty degeneration of hepatocytes was observed. The Disse space was enlarged. Around the interlobular veins, weak mononuclear infiltrations, often mixed with eosinophils, were noticed.

Severe renal hyperaemia was present. The epithelium of kidney tubules showed granular degeneration. A large number of the nuclei were pyknotic, another part with rexis and a third part lysed. A frequent finding was swollen and desquamated epithelial cells. In some places the epithelial cells of whole groups of ducts were disintegrated and desquamated (Fig. 3).

Hyperaemia of the spleen was moderate. Multiple eosinophilic granulocytes and single plasma cells were observed in the marginal sinuses. Haemorrhages and degenerative changes in Malpigean bodies were observed (Fig. 4).

In lungs, hyperaemia and haemorrhages were observed.

The epithelium of intestinal villi was partially desquamated. Hypertrophy of the goblet cells, hyperaemia, haemorrhages and perivascular clusters of eosinophils, mononuclear cells and siderocytes were present.

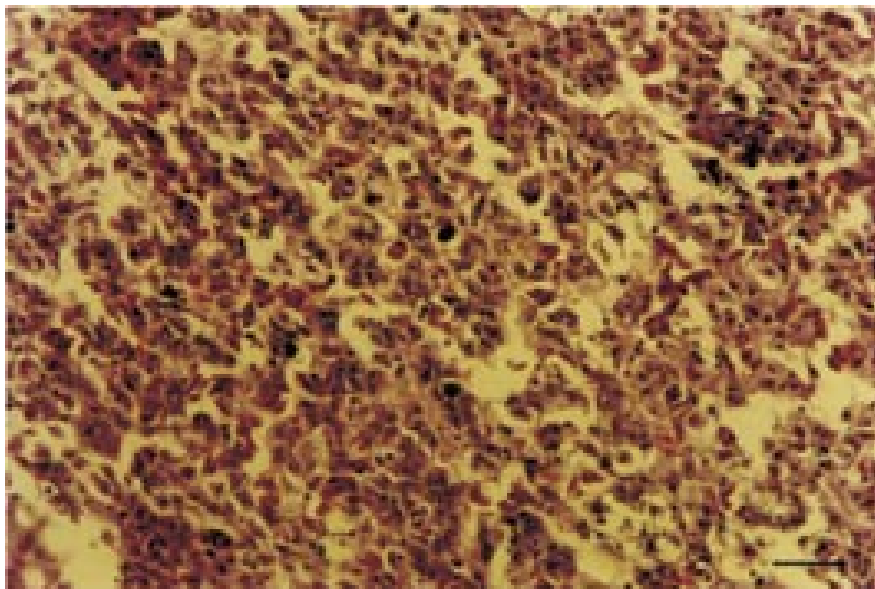


Fig. 3. Histopathological changes in the kidney of a chicken, experimentally infected with biting lice. Scale bar = 25  $\mu$ m.

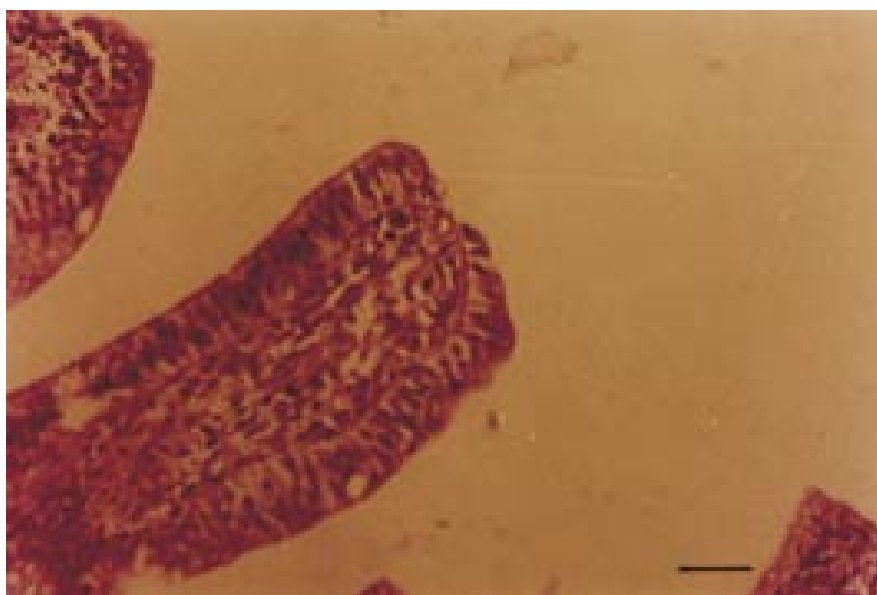

Fig. 4. Histopathological changes in the spleen of a chicken, experimentally infected with biting lice. Scale bar = 25  $\mu$ m.

## Discussion

Taking into account the fact that not one control bird died, and the uniform conditions of feeding and housing, it could therefore be assumed that the cause of death of the 5 experimental birds was mallophagosis. Similar results were obtained by DERYLO (1974) who observed a 30% death rate in Rhode Island Red hens experimentally infected with *Eomenacanthus stramineus*. AL-ANI et al. (1987) reported an increased death rate (by 10%) in Leghorn and New Hampshire hens infected with the same *Mallophaga* species. Increased mortality or decreased survival rate in other avian species with mallophagosis were observed by CAO-TIAN WEN and YAN-GUANG HUA (1990) in pheasants (*Crossoptilon mantchuricum*); CLAYTON and TOMPKINS (1995) in rock doves (*Columbia livia*) as well as LEE and CLAYTON (1995) in swifts (*Apus apus*).

MANN and RIBBECK (1973) and CLELAND et al. (1989) determined the rate of infestation of host (dove and sheep, respectively) with 100 and more lice as strong. BROWN (1972) reached a maximum intensity of 127 lice in an experimental *Menacanthus stramineus* infection of 40-day-old chickens. Considering those facts we believe that the intensity of invasion in our experiment was very high and caused the death of the 5 experimental chickens.

Similar changes on the skin of chickens with mallophagosis observed in our experiment were described by DERYLO (1974). In his opinion they could be caused by the direct attack of biting lice, drinking blood, or could be secondary following pecking and scratching as a result of the infestation-mediated systemic sensitization.

Such clusters of eggs that we found at the basis of feathers around the cloaca of the infected chickens were also described by HOHORST (1939).

The histopathological changes in the tissues of chickens that died following a severe experimental infestation with biting lice, observed in our study, indicated a general sensitization and intoxication of the organism (general hyperaemia, haemorrhages and haemosiderosis, eosinophilic and hystiocytic infiltration). A similar systemic allergic cutaneous reaction in *Eomenacanthus stramineus*-infected chickens was reported by DERYLO (1974) in birds. BANY et al. (1995) evidenced a lymphocytic proliferation in the peripheral blood and an increase in the prescapular lymph nodes in lambs, naturally infected by *Bovicola ovis*, as well as in lambs injected with *B. ovis* antigen with severity of the lesions, dependent on the degree of infestation. According to ZLOTORZYCKA et al. (1974) in a more extensive infestation there was toxic influence of *Mallophaga* on the host organism.

Desquamation of the villi of small intestine mucosa and the hypertrophy of the goblet cells (evidence by an enhanced mucus production) found in the present study could be explained by the occurring enteritis. These observations are further supported by the studies of CHENG (1964) who observed diarrhoea as well as prostration, body mass loss and decreased laying capability in hens infected by *Eomenacanthus stramineus*.

## Conclusions

The experimental mixed infestation with biting lice in chickens resulted in local and systemic pathomorphological changes, comprising cutaneous, muscular, spleen, liver, pulmonary, renal and intestinal haemorrhages. Hyperaemia, haemosiderosis, eosinophilic and histiocytic infiltration as well as dystrophic changes in the aforementioned organs and tissues, secondary to the intoxication and sensitization occurred. The more severe infestations of birds could result in a lethal issue.

## References

- AGARWAL, G. P., A. K. SAXENA, S. CHANDRA (1983): Haematophagous behaviour of *Menacanthus eurysternus* (*Mallophaga*, *Amblycera*). *Angew. Parasitol.* 24, 55-59.
- AL-ANI, I., A. K. A. AL-SOUDI, A. S. R. AL-OBAIDI (1987): The effect of chicken yellow body louse (*M. stramineus*) on some economic characters of different breeds and strains of chicken. *J. Agr. Water Resources Res. Anim. Prod.* 6, 1-11.
- BANY, J., A. PFEFFER, M. PHEGAN, A. C. HEATH (1995): Proliferative responses of lymphocytes in *Bovicola bovis* - infested lambs. *Int. J. Parasitol.* 25, 765-768.
- BROWN, N. S. (1972): The effect of host beak condition on the size of *Menacanthus stramineus* populations of domestic chicken. *Poultry Sci.* 51, 162-164.
- CAO-TIAN WEN, YUAN-GUANG HUA (1990): An investigation of *Mallophaga* on *Crossoptilon mantchuricum*. *Chinese J. Zool.* 25, 55.
- CHENG, T. C. (1964): *The Biology of Animal Parasites*, W.B. Saunders Company, Philadelphia, London. pp. 573-578.
- CLAYTON, D. H., D. M. TOMPKINS (1995): Comparative effects of mites and lice on the reproductive success of rock doves (*Columba livia*). *Parasitology* 110, 195-206.
- CLELAND, P. C., K. J. DOBSON, R. J. MEADE (1989): Rate of spread of sheep lice (*Damalinea ovis*) and their effects on wool quality. *Aust. Vet. J.* 66, 298-299.
- DE GEER, C. (1778): *Memoires pour servir a l'histoire des insectes*. *Des Ricins.* 7, 69-82.
- DERYLO, A. (1974): Studies on the economic harmfulness of biting lice (*Mallophaga*). I. The influence of biting lice infestation on the state of health of hens and turkeys. *Med. Wet.* 30, 353-357.
- DERYLO, A., E. GOGACZ (1974): Attempts to determine blood amount taken from hens by bird lice (*Eomenacanthus stramineus* Nitzsch) by using radioactive chromium as labelling factor. *Bull. Vet. Institute in Pulawy.* 18, 50-51.
- DUBININ, V. B. (1947): Studies on the adaptations. Ecological adaptations of the mallophagans and feather ticks. *Parasitologicheskii Sbornik Zoologicheskogo Instituta Akademii Nauk SSSR.* 9, 191-222 (in Russian).
- FABIYI, J. P. (1986): Exclusion in Nigeria of chickens and guinea-fowls from the host range of *Menacanthus stramineus* (*Mallophaga*: Insecta). *Revue D'Elevage et de Medicine Veterinaire des Pays Tropicaux.* 39, 377-379.



P. N. Prelezov et al.: Pathomorphological changes in the tissues of chickens, experimentally infected with biting lice

- HALLIGAN, G., A. C. JOHNSTONE (1992): Histology of cockle of New Zealand lamb skins. J. Am. Leather Chem. As. 87, 39-51.
- HOHORST, W. (1939): Die Mallophagen des Haushuhnes und ihre Eigelege. Veter.- Med. Nachr. 4, 61-87.
- JAMES, P. J., R. D. MOON (1998): Pruritis and dermal response to insect antigens in sheep infected with *Bovicola ovis*. Int. J. Parasitol. 28, 419-427.
- LEE, P. L. M., D. H. CLAYTON (1995): Population biology of swift (*Apus apus*) ectoparasites in relation to host reproductive success. Ecol. Entomol. 20, 43-50.
- MANN, H. G., R. RIBBECK (1973): Untersuchungen zum Vorkommen von Mallophagen bei Haustauben, *Columba livia domestica*, speziell bei Sporttauben. Lounais-Hämeen luonto. 46, 73-77.
- MCCLURE, H. E. (1989): Enzootic lesions of house finches in Ventura Country, California. J. Field Ornithol. 60, 421-430.
- MOCK, D. E. (1977): The cattle biting louse *Bovicola bovis* (Linn.). I. In vitro culturing, seasonal population fluctuations and role of the male. II. Immune response of cattle. Ph.D. Thesis, Cornell University.
- PFEFFER, A., J. S. BANY, M. D. PHEGAN, P. J. OSBORN (1994): Hypersensitivity skin testing of lambs infested with the biting louse (*Bovicola ovis*). New Zealand Vet. J. 42, 769.
- WATERSON, J. (1926): On the crop contents of certain *Mallophaga*. Proceeding Zool. Soc. London. 96, 1017-1020.
- ZLOTORZYCKA, J., W. EICHLER, H. W. LUDWIG (1974): Taxonomie und Biologie der Mallophagen und Läuse mitteleuropäischen Haus- und Nutztiere. 1. Auflage. VEB. Gustav Fischer Verlag, Jena. p. 138.

Received: 9 June 2004

Accepted: 2 May 2006

---

**PRELEZOV, P. N., N. I. GROSEVA, D. I. GOUNDASHEVA: Patološkomorfološke promjene u tkivu pilića pokusno invadiranih paušima (Insecta: *Phthiraptera*). Vet. arhiv 76, 207-215, 2006.**

**SAŽETAK**

U radu je prikazana smrtnost i patološkomorfološke promjene u tkivu pilića invadiranih paušima *Eomenacanthus stramineus* Nitzsch (1818), *Menacanthus cornutus* Schömmmer (1913), *Menopon gallinae* L. (1758) i *Goniocotes gallinae* DeGeer (1778). Od ukupno 20 pokusno invadiranih životinja, pet ih je uginulo (25%-tna smrtnost). Uginuli pilići razučeni su te je tkivo kože, mišića, slezene, jetara, pluća i bubrega pretraženo makroskopski i histološki čime su dokazane mnoge rane i krvarenja, osobito u koži. Osim navedenoga, u koži i drugim pretraživanim tkivima utvrđena je hiperemija, krvarenja, hemosideroza, pseudoeozinofilna i histiocitna infiltracija. Zabilježena je i upala tankih crijeva. Utvrđene promjene bile su izražene lokalno i po čitavom organizmu. Lokalne ozljede bile su uzrokovane izravno paušima, dok su sustavne promjene vjerojatno bile uzrokovane senzibilizacijom i intoksikacijom na ugriz pauši.

**Ključne riječi:** *Phthiraptera*, *Mallophaga*, pilići, patomorfologija, hiperemija, hemosideroza

---

