

Morphology and Prevalence of the Louse *Haematomyzus elephantis* in Captive Asian Elephants in Sri Lanka

H. V. Waruna Suranga¹, Ashoka Dangolla^{1*}, Chandana Rajapakshe² and R. P. V. Jayantha Rajapakse³

¹Department of Veterinary Clinical Sciences, University of Peradeniya, Peradeniya, Sri Lanka

²Pinnawela Elephant Orphanage, Pinnawela, Kegalle, Sri Lanka

³Department of Veterinary Pathobiology, University of Peradeniya, Peradeniya, Sri Lanka

*Corresponding author's e-mail: adangolla@gmail.com

Introduction

The biting louse *Haematomyzus elephantis* is only found on elephants and is more of a scavenger than a parasite (Gomez 2000; Fowler & Mikota 2006). Drought conditions are more favourable for lice and egg cases of lice (nits) can be more commonly seen attached to hair of elephants during dry periods (Fowler & Mikota 2006). Captive elephants need to be treated when they get infested with parasites including lice. *H. elephantis* has been reported from captive elephants in India (Sudan *et al.* 2015).

H. elephantis is dorso-ventrally flattened, with a segmented body. The head consists of segmented antennae and a rostrum with mandibles that are developed as biting organs. Three pairs of legs, each with five segments, emerge from the thorax. The abdomen, which has six pairs of spiracles, is the longest part of the body. Females are comparatively larger and longer (Wall & Shearer 2001).

This study was conducted to detect the prevalence of lice on Asian elephants (*Elephas maximus*) in Pinnawela Elephant Orphanage (PEO) and privately owned captive elephants, and to examine the morphology of *H. elephantis* in Sri Lanka.

Materials and methods

During March to July 2014, all 77 elephants at PEO and 15 privately owned elephants were visually examined for the presence of lice with special emphasis on skin crevices or soft skin of the ears, the throat, around the mouth, ventral surface of the trunk near its base, the abdomen

and the tail. Approximately 20–30 minutes were spent examining each animal. Skin examination of an elephant for more than 20 minutes is difficult because the elephants would not keep still for long, especially for detection of lice, and therefore, early morning or late evening was used for examinations because elephants are cooperative at that time due to lower environmental temperature. On some occasions, lice on the tail were collected while the elephant was bathing and being scrubbed. An elephant was considered infected when at least one louse was found.

Samples of lice were preserved by adding 70% alcohol. In the laboratory, specimens were cleared using potassium hydroxide and were mounted on glass slides. Species identification using morphology was done according to Mullen and Durden (2002), Wall and Shearer (2001) and Yoshizawa and Johnson (2006). A binocular dissection microscope with a micrometer scale and a light microscope were used to examine and measure the specimens. Morphometric measurements including total length, length of the rostrum, head, thorax, abdomen and antennae were made on 10 male and 10 female lice.

Results

Out of the 92 elephants examined, 82 were infested with lice, giving an overall prevalence of 89%. In PEO, the prevalence was 100% and in privately owned elephants 33%. The microscopic appearance of a male and a female louse are shown in Figures 1 and 2 respectively and measurements of 10 individuals of each sex are given in Table 1.

Table 1. Morphometrics of *Haematomyzus elephantis* (mean \pm SE, in mm).

Gender	Rostrum	Head	Thorax	Abdomen	Total	Antenna
Male (n = 10)	0.504 \pm 0.03	0.289 \pm 0.03	0.319 \pm 0.03	0.931 \pm 0.05	2.044 \pm 0.09	0.643 \pm 0.03
Female (n = 10)	0.642 \pm 0.03	0.357 \pm 0.04	0.367 \pm 0.02	1.607 \pm 0.11	2.973 \pm 0.11	0.725 \pm 0.02

Discussion

We found a high prevalence of lice in captive elephants in Sri Lanka. The prevalence of *H. elephantis* in wild elephants in Kruger National Park was 58% (Braack 1984) and its occurrence in captive elephants in India has been reported as rare (Sudan *et al.* 2015). Therefore a surprisingly high prevalence of lice was found in captive Sri Lankan elephants, especially at the PEO where it was 100%. The constant close physical contact among elephants at PEO could be attributed to this high prevalence.

In comparing the two groups in our study, we found the prevalence of lice in PEO elephants to be much higher than in privately owned elephants. The two groups of elephants were

managed differently. Elephants at PEO do not have individual keepers, are not scrubbed individually when bathing and freely interact with each other throughout the day. Privately owned elephants have individual keepers and assistants, are bathed and scrubbed at least once daily, and are mostly kept as individual animals with little or no interaction with other elephants. Therefore, the difference in prevalence between the two groups in our study could be related to variation in management practices.

Most keepers of the elephants used in this study were unaware of elephant lice, although some stated that a biting insect could be present on the elephants. Some keepers indicated that elephant lice had bitten them, leading to mild irritation, pruritus and a local reaction. We have observed

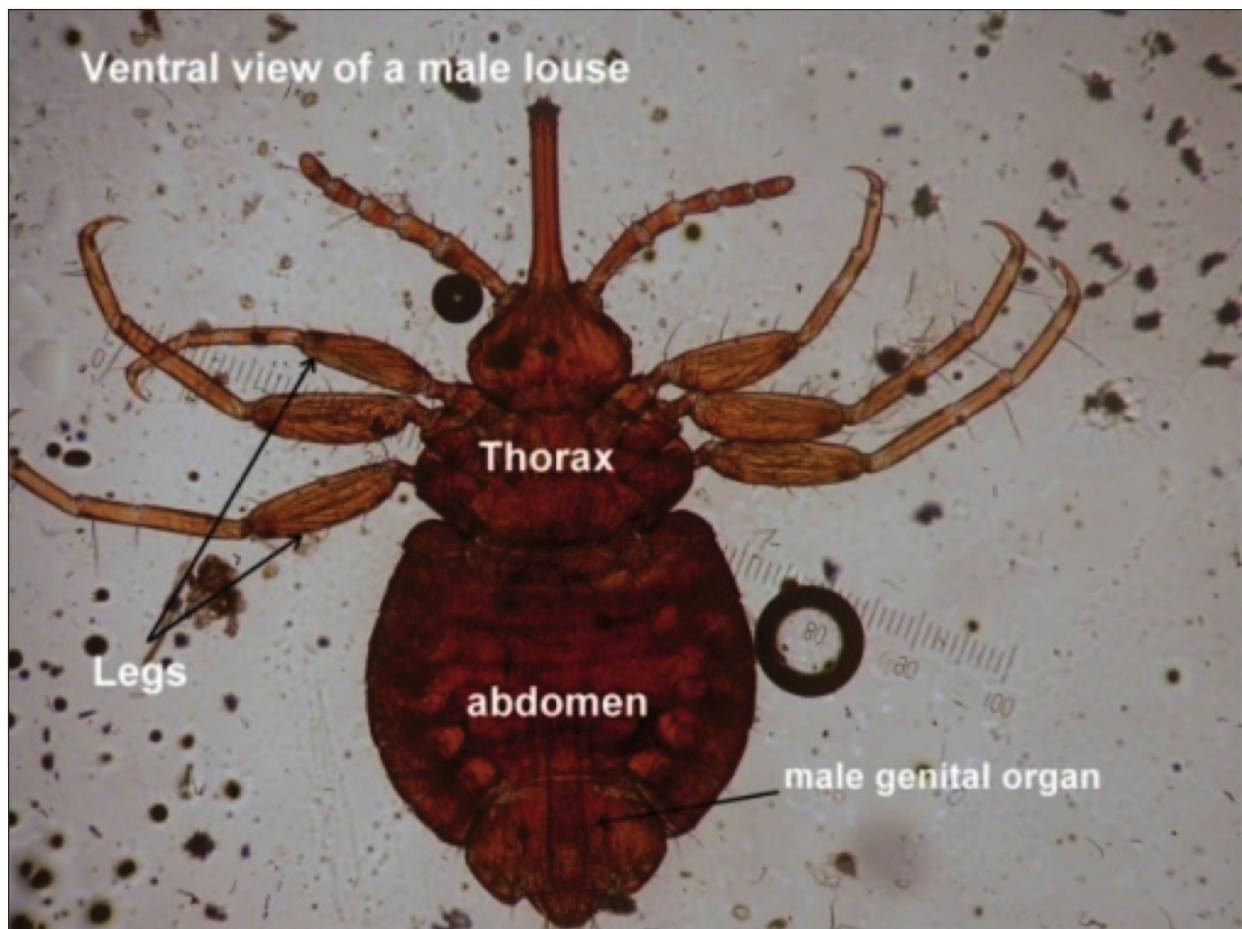


Figure 1. Male elephant louse.

some elephants infested with lice to be restless or hyper-irritable and to dash their tail against hard objects or sides of the body, which may lead to injury. We have successfully treated captive elephants infested with *H. elephantis* with pyrethrins, organic phosphates and ivermectine injections.

The morphology of the lice reported herein is in agreement with the description of *H. elephantis* in Wall and Shearer (2011). Similar species *H. porci* (pig lice) and *H. hopkinisi* (warthog lice) have a much shorter rostrum (Wall & Shearer 2001). Morphologically *H. elephantis* appears to be a sucking louse because of the rudimentary proboscis on the long rostrum, though it has been classified as a biting louse because of the strong mandible on the rostrum (Gomez 2000). It is worth examining why the mouthparts, specially the rostrum, of *H. elephantis* are longer than in any other biting louse.

Acknowledgement

We wish to thank Dr. Dilini C. Weerathunge and Dr. Lasanthika Dushyanthi of the Department of Pathobiology of the University of Peradeniya, Mr. Sanjaya Rathnayake and all elephant keepers at Pinnawela Elephant Orphanage, Mr. Sandith Samarasinghe of Millenium Elephant Foundation and all owners and keepers of privately owned elephants used in this study.



References

Braack LEO (1984) A note on the presence of the elephant louse *Haematomyzus elephantis* (Mallophaga: Rhynchophthirina) in the Kruger National Park. *KOEDOE African Protected Area Conservation Science* **27(1)**: 139-140.

Fowler ME & Mikota SK (2006) *Elephant Biology, Medicine and Surgery*. John Wiley and Sons, USA.

Gomez P (2000) *Haematomyzus elephantis*. Animal Diversity Web. Accessed 27.12.2015 at <http://animaldiversity.org/accounts/Haematomyzus_elephantis/>

Mullen G & Durden LA (2002) *Medical and Veterinary Entamology*. 2nd Edition. Elsevier Publication.

Sudan V, Jaiswal AK & Shanker D (2015) A rare documentation of *Hematomyzus elephantis* lice from elephants of Mathura. *Journal of Parasitic Diseases* **39**: 793-794.

Wall R & Shearer D (2001) *Veterinary Entomology: Arthropod Parasites of Veterinary Importance*. 1st Edition. Chapman and Hall, London, UK.

Yoshizawa K & Johnson KP (2006) Morphology of male genitalia in lice and their relatives and phylogenetic implications. *Systematic Entomology* **31**: 350-361.

Figure 2. Female elephant louse.