

UDC 636.596:619:576.895.751.4

## BIRD LICE (MALLOPHAGA, PHILOPTERIDAE, MENOPONIDAE) OF DOMESTIC PIGEONS ON SPECIALIZED PIGEON BREEDING FARMS IN POLTAVA

I. O. Kolomak, O. V. Kruchynenko

Poltava State Agrarian Academy, Skovorody st., 1/3, Poltava, 36003 Ukraine  
E-mail: igor.kolomak@mail.ru

**Bird Lice (Mallophaga, Philopteridae, Menoponidae) of Domestic Pigeons on Specialized Pigeon Breeding Farms in Poltava. Kolomak, I. O., Kruchynenko, O. V.** — The species composition of pigeon lice parasitic on pigeons of ornamental breeds on the specialized closed-type farm (Poltava) was studied. Five species of these ectoparasites were registered: *Columbicola columbae* Linnaeus, 1758, *Campanulotes compar* Burmeister, 1838, (Philopteridae, Ischnocera), *Bonomiella columbae* Emerson, 1957, *Hohorstiella lata* Piaget, 1880 and *Neocolpocephalus turbinatum* (Denny, 1842) (Menoponidae, Amblycera). For each species, the data on infection prevalence, intensity and abundance were obtained. High prevalence of infection was registered for all pigeon lice species, while the intensity and, especially, the abundance were considerably different. *C. columbae* turned out to be the most abundant. *B. columbae* was rather common. The peculiarities of pigeon lice species localization on the host body were investigated. During the intensive infection of pigeons with lice, the complex of clinical signs is manifested, which testifies about considerable effect of these parasites on the host. The highest pathogenicity is characteristic for *H. lata*, which usually feeds on blood and lymph.

Key words: pigeon lice, *Columba livia domestica*, *Columbicola columbae*, *Bonomiella columbae*, *Hohorstiella lata*, *Campanulotes compare*.

### Introduction

Specialized breeding of ornamental domestic pigeon breeds is a new field of poultry farming which appeared in Ukraine not long ago and has successfully been developing during the recent years. Infective diseases are one of the restraining factors of this direction in poultry breeding. Enzootic outbreaks of viral and bacterial infections are rather often registered in domestic pigeons, as well as diseases caused by protozoans, helminths, arthropod ecto- and endoparasites.

Ectoparasites are the important component of parasite communities in domestic and wild animals. Bird lice (Mallophaga) are common and wide-spread group of ectoparasites of pigeons. They were actively studied in Ukraine in the 60–80s of the last century (Fedorenko, 1983; Kharambura, 1978, and others). There is also

information about species composition of domestic and wild pigeons' lice (Fedorenko, Kharchenko, 1976). Veterinary parasitologists paid little attention to studying lice of various poultry and their pathogenic impact on bird hosts. The ectoparasites were mainly investigated in domestic hens, ducks, and geese. After a many-year break, new publications dealing with lice have appeared. In particular, N. M. Soroka and I. V. Sydorenko (2013) published the results of studies of the species composition of pigeon lice, and the methods of diagnostics and treatment of these birds' mallophagoses. A monograph on bird lice of Moldova and Western Ukraine has been recently published (Lunkashu et al., 2008).

According to the literature data, 5 species of domestic pigeons' lice have been registered in Ukraine: *Columbicola columbae*, *Campanulotes compar* and *Bonomiella columbae* (Philopteridae, Ischnocera); *Hohorstiella lata*, *Neocolpocephalus turbinatum* (Menoponidae, Amblycera). About 20 species of lice are known in domestic and wild pigeons worldwide.

In case of the considerable infection intensity, lice cause the diseases of the infected birds (mallophagoses). Besides, they can be intermediate hosts of some helminthes (filariae and others) and also the vectors of viral and bacterial infections. The diseases are manifested by a clearly expressed syndrome, which is characterized by strong restlessness, pruritus, skin reddening, dermatitis, feathers' lesion, decreasing of the general body weight and egg-laying rate. All these factors considerably decrease the reproductive efficiency, ornamental qualities, and flight activity of pigeons, correspondingly decreasing the cost of birds.

Moreover, domestic pigeons actively contact with synanthropic populations of feral domestic and wild species of pigeons occurring in populated areas. As a result, the exchange of parasites, including lice, takes place. That is why studying parasites of various groups of pigeons is the important task for successful breeding of valuable breeds of these birds.

## Materials and methods

During 2016–2017 we studied the parasites, including pigeon lice, on the closed-type pigeon-breeding farm located in the town of Poltava. In total, 55 pigeons were examined.

The examination of birds was carried out according to N. M. Dubinina's methods (Dubinina, 1971). Intensity and prevalence of infection, as well as pigeon lice localization in different areas of plumage were taken into account. The specimens were examined and identified using the light microscope Zeiss Axio Imager M1 at I. I. Schmalhausen Institute of Zoology (Kyiv, Ukraine).

## Results

All the four species of pigeon lice known in Ukraine have been found on the pigeon breeding farm: *B. columbae*, *H. lata*, *C. compar*, *C. columbae* (table 1). *Columbicola columbae* (fig. 1, a, fig. 2) is one of the most abundant species of pigeon lice on the investigated pigeon-breeding farm (table 1). The prevalence of infection is 100 %, the average infection intensity is 9.3, 495 specimens were collected; the abundance is 9.0 specimens. This species is mainly localized on flight and contour feathers, exactly between the barbules of the first and second succession. During the autumn-winter period the population of ectoparasites on birds decreases insignificantly. Also, during this period, they changed their localization, moving closer to the host body; in the majority of cases they moved to the internal surface of flight wing feathers. It is the biggest species, reaching the body length up to 2.7 mm. Sex dimorphism is manifested in the difference of the body length, which is 2.4–2.7 mm in females, and 2.0–2.2 mm in males (table 2). Besides, males have longer and thicker first antennal segment, than females.

**Table 1. Infection parameters of pigeon lice species on the investigated farm**

Species	Prevalence of infection, %	Infection intensity, sp.
<i>Columbicola columbae</i>	100	9.3 ± 1.5
<i>Bonomiella columbae</i>	100	4.3 ± 1.3
<i>Hohorstiella lata</i>	72.7	3 ± 1.8
<i>Campanulotes compar</i>	41.8	2 ± 1.2

Mean ± SD (min–max)

*Bonomiella columbae* (fig. 3, a) is also often met on the pigeons of this farm. The prevalence of infection is 100 %, the average infection intensity is 4.3, 165 specimens were collected; the abundance is 3.0 specimens. The females in this species, as well as in the previous one, are bigger (1.8–1.9 mm), than males (1.0–1.5 mm) (table 2). The localization of this pigeon lice species differs from the former one. The



Fig. 1. Fam. Philopteridae: *a* — *Columbicola columbae* — general view; *b* — *Companulotes compare* — head; *c* — *Companulotes compare* — general view.

parasites are mainly localized nearer to the skin covering, they can also be found on accessory feathers and abdomen areas covered with down. They feed on down or lymph and blood. *B. columbae* is distinguished by considerable chitinization of the head and lateral parts of the thorax. This species is more mobile than the former one and differs from the other species by pale coloring. The degree of pigmentation somewhat increases on the head, feet, and on the tip of the abdomen. Despite their active movements, it is difficult to notice them among feathers. *B. columbae* differs from the other found species by a small head with prominent clypeus, and also the different shape and length of antennae. Their feet are thin and long.

*Hohorstiella lata* (fig. 3, *b*) is the species which is usually met in insignificant numbers, having rather high prevalence of infection (72.7 %); 40 pigeons were infected, the average infection intensity was 3.1, 110 specimens were collected, the abundance was 2.0. The body length of the female reaches 2.3–2.5 mm, males are smaller, up to 1.8 mm (table 2). In the majority of cases these pigeon lice parasitize on the bird cutaneous covering in the

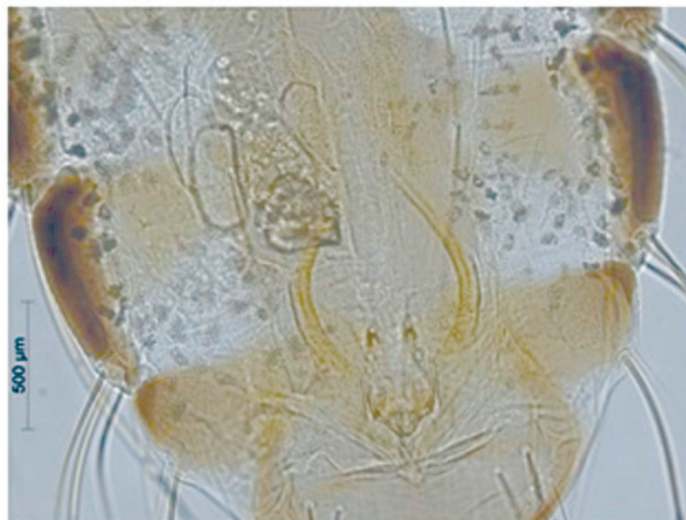


Fig. 2. Male copulatory apparatus *Columbicola columbae*.

**Table 2.** Body length in females and males of studied pigeon lice species

Species	Body length, mm	
	females	males
<i>Columbicola columbae</i>	2.50 ± 0.06 (2.4–2.7)	2.10 ± 0.04 (2.0–2.2)
<i>Bonomiella columbae</i>	1.73 ± 0.04 (1.7–1.8)	1. ± 0.04 (1.0–1.1)
<i>Hohorstiella lata</i>	2.31 ± 0.07 (2.3–2.5)	1.61 ± 0.04 (1.5–1.7)
<i>Campanulotes compar</i>	2.3 ± 0.05 (2.3–2.5)	2. ± 0.03 (2.1–2.3)

area of thorax and abdomen, mainly, in places covered with down, on which they feed, and also on down parts of small feathers. The shape of the second antennal segment, narrowing to the top, is a distinctive peculiarity of this species. Besides, there is a long finger-shaped appendage on this antennal segment. The last antennal segment is the biggest and it is stretched in length unlike the former one. The dimensions of males and females are also considerably different. The pigeon lice of this species are very mobile, they actively move in down covering.

*Companulotes compare* (fig. 1, b, c) is the least numerous pigeon lice on the given farm. The prevalence of infection was 41.8 %, 23 pigeons were infected, the average infection intensity was 2.0, 83 specimens were collected, the abundance was 1.5. The body length of the female is 2.3 mm, males — up to 2.1 mm (table 2). They are localized on the bird body directly on the derma or additional feathers. A fan-shaped head, rounded clypeus with several hairs, the median ones are considerably longer, than the others, are the peculiarities of this species. The male antennary sinus is deep, having the bristle on the frontal area. The male first antennal segment is thicker, the second one has the top appendage, the third segment is curved, and the last two antennal segments are very short. The abdomen of the male is wide, unlike that of the female, which has the abdomen of lengthened-oval shape.

The shape and body dimensions are related to the parasite localization on the host body. *C. columbae* has a thin and long body, which enables to fix well between the barbules of the primary and secondary succession. *B. colombae*, *H. lata*, and *C. compar* have the body of rounded, flattened form, which is convenient for the localization directly on the skin and enables the parasite to remain on the accessory downy feathers.

Sex dimorphism is peculiar for all pigeon lice species revealed by us: males are smaller, than females (table 2).



Fig. 3. Fam. Menoponidae: a — *Bonomiella columbae* — general view; b — *Hohorstiella lata* — general view.

According to our data, the dimensions of some pigeon lice species are bigger, than it is mentioned in the literature.

The frequency of co-occurrence of pigeon lice species was determined. All the four pigeon lice species were found in 41.8 % of pigeons, and the total specimens' number of each species was the following: *C. columbae* — 207 specimens; *B. columbae* — 69 specimens; *H. lata* — 61 specimens; *C. compar* — 83 specimens.

Three-species communities were found in 17 pigeon specimens (30.9 %) with the following number of lice specimens: *C. columbae* — 153 specimens; *B. columbae* — 51 specimens; *H. lata* — 50 specimens.

Two-species communities were found in 15 pigeons (27.3 %) with the following number of specimens: *C. columbae* — 135 specimens; *B. columbae* — 45 specimens.

One-species communities were not found.

Two species of pigeon lice form the basis of the community, parasitizing on one individual host: *C. columbae* and *B. columbae*; they considerably differ as to their localization on the host body. They were found in all the examined pigeons. Rather often *B. columbae* and *H. lata* were combined and they were found on the body of 40 birds. These two species are localized on the thorax and abdomen of the pigeons. *C. compar* was the most rarely found species; it was found only on the body of 23 birds. It is localized directly on the host derma. Its number is not high comparatively to other pigeon lice species. Apparently, the competition among the micro-populations of pigeon lice species, localizing on one individual host, is absent.

## Conclusions

1. Five pigeon lice species were found on the pigeon-breeding farm surveyed by us: *C. columbae*, *B. columbae*, *C. compar*, *H. lata* and *N. turbinatum*. The latter species was found in domestic pigeons of Ukraine for the first time.

2. *C. columbae* and *B. columbae* turned out to be the most abundant pigeon lice species, with the prevalence of infection 100 % and the abundance 9.0 and 3.0, correspondingly. The prevalence of infection of *H. lata* is also rather high, 72.7 %, the abundance is 2.0. *C. compar* was registered rarely: the prevalence of infection was 41.8 %, the abundance 1.5.

3. The relationships between the body shape of the identified pigeon lice species and the peculiarities of their localization on the pigeon body were registered. *C. columbae*, localizing on the vexilla of large flight wing feathers, has a narrow, lengthened body shape. All the other three species, localizing on small covert feathers on the thorax and abdomen of birds, have more flattened body shape with a wide abdomen.

4. Pigeon lice form multi-species communities, commonly occurring on one individual bird. All the four species were found most frequently, in 41.8 % of birds. Three-species communities, in which *C. compare* was absent, were found in 30.9% of cases. Two-species communities were registered rarely (27.3 %).

5. At the intensive infection of pigeons with lice, the complex of clinical signs testifying about considerable pathological impact of ectoparasites on the host was registered. The most pathogenic species is *H. lata* feeding mainly on blood. Mallophagoses can bring considerable losses to farms and need further attention and investigation.

The authors are grateful to research scientists of the Department of Parasitology of I. I. Shmalgausen Institute of Zoology of the National Academy of Sciences of Ukraine O. B. Hreben, V. V. Korniyshyn, and Yu. I. Kuzmin for their assistance in identifying the collected pigeon lice and valuable advice in preparing this work for publication.

## References

- Dubinina, M. N. 1971. *Parasitological Investigation of Birds*. Nauka, Leningrad, 1–137.  
 Fedorenko, I. O. 1983. Lice, biting lice. Is. 5: Pigeon Lice: Menoponides. Part 1. Somanphantodes, Menoponides, Pseudomenoponides Families. In: *Fauna of the Ukraine, Vol. 22*. Naukova Dumka, Kiev, 1–168.

- Fedorenko, I. A., Kharchenko, V. I. 1976. On the record of *Bonomiella columbae* Emerson (Mallophaga) in Ukraine. *Vestnik Zoologii*, 3, 84.
- Kharambura, Ya. 1978. The Materials to the Fauna of the Bird Lice (Insecta, Mallophaga) Cultural Landscapes of the Ukrainian SSR. *Vestnik Zoologii*, 4, 90–92.
- Lunkashu, M., Erkhan, D., Rusu, S., Zamornia, M. 2008. Lice (Insecta: Mallophaga) of poultry and wild birds of Moldova and Western regions of Ukraine. Tipograf. AȘM, Chișinău, 1–376.
- Soroka, N. M., Sydorenko, I. V. 2013. Biting Lice Fauna, Phthiraptera Line, Ischnocera I amblycera Sub-Line of *Columba livia* in Ukraine. *Vestnik Zoologii*, 47 (3), 211–217.

Received 28 April 2017

Accepted 24 October 2017