



Contents lists available at ScienceDirect

Saudi Journal of Biological Sciences

journal homepage: www.sciencedirect.com

Original article

The prevalence and intensity of external parasites in domestic pigeons (*Columba livia domestica*) in Egypt with special reference to the role of deltamethrin as insecticidal agent

Heba M. Salem^{a,*}, Nahed Yehia^b, Saad Al-Otaibi^c, Ahmed M. El-Shehawi^c, Alia A.M.E. Elrys^d, Mohamed T. El-Saadony^e, Marwa M. Attia^f^a Department of Poultry Diseases, Faculty of Veterinary Medicine, Cairo University, 12211 Giza, Egypt^b Reference Laboratory for Veterinary Quality Control on Poultry Production, Animal Health Research Institute, Agriculture Research Center, Giza 12618, Egypt^c Department of Biotechnology, College of Science, Taif University, P.O. Box 11099, Taif 21944, Saudi Arabia^d School of Life Science, Nanjing Normal University, Nanjing, Jiangsu, PR China^e Department of Agricultural Microbiology, Faculty of Agriculture, Zagazig University, Zagazig 44511, Egypt^f Department of Parasitology, Faculty of Veterinary Medicine, Cairo University, 12211 Giza, Egypt

ARTICLE INFO

Article history:

Received 23 August 2021

Revised 4 October 2021

Accepted 15 October 2021

Available online 22 October 2021

Keywords:

*Dermanyssus gallinae*Deltamethrin, *Hippobosca equina**Menopon gallinae**Knemidocoptes* spp., *Pseudolynchia**canariensis*

ABSTRACT

This study aimed to investigate the prevalence and intensity of external parasites in domestic pigeons in Giza, Egypt, from January 2020 to December 2020. A total of 300 domestic pigeons (25 pigeons per month) were examined. The birds were divided into groups based on their age. The oxidative stress parameters; serum zinc concentration, serum malondialdehyde (MDA), and serum Nitric oxide were evaluated in single and mixed external parasitic infestations. The prevalence of external parasites in examined pigeons was 80.3%. The detected parasites were *Pseudolynchia canariensis* (*P. canariensis*), *Hippobosca equina* (*H. equina*), *Columbicola columbae* (*C. columbae*), *Menopon gallinae* (*M. gallinae*), *Knemidocoptes* species (spp.) and *Dermanyssus gallinae* (*D. gallinae*); their incidences were 41.6, 26, 7, 5, 0.33 and 0.33%, respectively. The highest infestation was recorded in both spring and summer. The incidence of disease was higher in squabs and young birds than in adults. The mixed external parasitic infestation was recorded in this study. The infected birds showed decreased serum zinc concentration and elevated MDA and serum Nitric oxide levels. In conclusion, regular monthly treatment with deltamethrin is recommended as an effective drug in the treatment of the infested birds and succeeded in reducing the incidence of external parasites in the treated birds; in addition, pigeon management measures must be implemented to reduce the risk of external parasites.

© 2021 The Author(s). Published by Elsevier B.V. on behalf of King Saud University. This is an open access article under the CC BY-NC-ND license (<http://creativecommons.org/licenses/by-nc-nd/4.0/>).

Abbreviations: MDA, serum malondialdehyde; *P. canariensis*, *Pseudolynchia canariensis*; *H. equina*, *Hippobosca equina*; *C. columbae*, *Columbicola columbae*; *M. gallinae*, *Menopon gallinae*; *D. gallinae*, *Dermanyssus gallinae*; spp., Species.

* Corresponding author.

E-mail addresses: dr.hebasalem@cu.edu.eg (H.M. Salem), elshehawi@hotmail.com (A.M. El-Shehawi).

Peer review under responsibility of King Saud University.



Production and hosting by Elsevier

1. Introduction

Pigeons coexist with different animal and poultry species as well as humans all over the world (Alkharigy et al., 2018). In Egypt, domestic pigeons are a valuable source of essential protein for people as they gain more weight quickly than other birds, its meat is palatable, easy to breed, and require slight management (El-Dakhly et al., 2016). Pigeons can be infected with a wide range of pathogens and serve as a reservoir for parasitic diseases. The proximity of pigeons to other domestic birds heightens the risk of parasitic infestation in poultry (Alkharigy et al., 2018). Pigeons harbor both external and/or internal parasites (Attia and Salem 2021).

Poultry ectoparasites are abundant in the tropics, where poor husbandry practices and favorable climatic circumstances allow

them to thrive (Imura et al., 2012; Badparva et al., 2015; Salem and Attia 2021). These parasites induce several direct and indirect effects on the pigeon, including weight loss, irritability, decreased productivity, malnutrition, low growth, decreased egg production and the development of a variety of clinical symptoms as; ruffled broken feathers, feathers loss, itching, pruritis, dermatitis, emaciation, inconvenience, death especially in squabs as well as indirect harm by transmitting other diseases (Radfar et al., 2012, Attia and Salem, 2021). The most common external parasites infesting pigeons are *P. canariensis*, *Argas persicus*, *D. gallinae*, *M. gallinae*, *C. columbae*, and *Menocanthus stramineus* (Atkinson et al., 2008).

Insects can harbor a lot of pathogens and convey them to the host from these pathogens “blood parasites” as *Haemoproteus columbae* which transmitted by the bite of ectoparasitic hippoboscids flies (Hussein and Abdelrahim, 2016); *Plasmodium relictum*, which is one of the most common species of avian malaria (Beadell et al., 2006) and *Leucocytozoon marchouxi* (Swinerton et al., 2005, Martinsen et al., 2006, Hussein and Abdelrahim 2016). Deltamethrin (a pyrethroid derivative) has become a popular pesticide in many nations due to its low toxicity and wide safety margin for poultry (Eladi et al., 2018). Deltamethrin affects the nervous system of insects that touch or ingest them, which leads to the rapid paralysis and death of these insects (Elyazar et al., 2011). In the same way, deltamethrin considered as an effective insecticide for the control of insects on pigeons and the surrounding environment (Attia and Salem, 2021). Accordingly, the aim of this study is to understand the biodiversity and determine the prevalence of pigeon external parasitic infestation with evaluation of oxidative stress markers and zinc levels which will aid in the planning of actions to improve the health of these birds in Egypt.

2. Material and methods

2.1 vvv. Ethical approval

This study was designed according to the Ethical Committee, Faculty of Veterinary Medicine regulations. Birds were humanly handled and safely released after clinical investigations.

2.2. Pigeon sampling

During the observation period from January to December 2020, 300 pigeons (25 bird per month) were investigated. Three hundred Birds were collected from different poultry clinics, poultry market and pigeon rearing houses from Giza, Egypt which lies in 29.9870°N 31.2118°E with a hot desert climate. The average ambient temperature in Giza in winter ranged from 21.1 °C (70.0)°F: 24.2 °C (75.6)°F with relative humidity 46:57%, in spring, 28.4 °C (83.1)°F : 34.9 °C (94.8)°F with relative humidity 37:44%, in summer 34.5 °C (94.1)°F : 41 °C (106)°F with relative humidity 39:53% and in autumn 25 °C (77.7)°F : 32.4 °C (90.3)°F with relative humidity 47: 57%. The examined birds were divided according to age as 80 squabs (day old to one month), 100 young (form one month to 7 months old) and 120 adults (above 7 months of age). Every bird was physically examined to detect the age and presence of external parasites (data were retrieved from the owners).

2.3. History and clinical examination of pigeons

2.3.1. External parasites

The feathers and skin were carefully examined for the presence of any macroscopic external parasites by naked eye then parasites were picked up and/ or skin scraping was adopted to identify the parasites using an Olympus Stereoscopic microscope (SZX16; Japan (Soulsby 1986; Attia and Salem, 2021).

2.4. Identification of the parasites

All the collected parasites from the birds and their premises were preserved in 70% ethyl alcohol. Then, these parasites were identified using the keys recorded by Soulsby (1986); Attia and Salem, (2021).

2.5. Blood samples

Blood was collected from jugular vein of externally parasitized birds on plain tubes for sera separation. Sera were kept on –20 °C for further investigations according to Attia et al., (2020).

2.6. Biochemical analysis

Serum zinc concentration were analysed using ionized coupled plasma by mass spectrometry method as described by Page et al., (2018); Attia et al., (2020).

2.7. Evaluation of oxidative stress markers

The level of serum malondialdehyde (MDA) using the reaction of thiobarbituric acid and then separation occurred on HPLC. The detection was performed using UV at 532 nm. Serum Nitric oxide (NO) level were analysed as mentioned by Khazaei and Nematbakhsh, 2012; briefly; colorimetric NO assay kit was used (Calbiochem-Novabiochem Corporation, San Diego, Calif), that measures the total nitrate and nitrite on serum based on Griess reaction and measured using wavelength 450 nm as mentioned by Aktas et al., (2017) and Aytakin and Unubol Aypak (2011).

2.8. Recommendation for external parasites control

Deltamethrin (Butox, 12.5 % solution, 1 mL / 4 L of water for birds & 1 mL /L for surrounding environment), is recommended for monthly spraying. Precautions have been taken during deltamethrin spraying, and the remains have been disposed of in a sanitary manner.

2.9. Statistical analysis

Data were statistically analyzed by using SPSS Version 18.0 software (Inc., Chicago, IL, USA). Blood parameters in infested and control non infested group were compared by independent T-test following the normality of data. A *p*- value consider significant when (*p* < 0.05).

3. Results

3.1. History and clinical investigations

Investigated pigeons were exhibited indications of illness such as general weakness, decreased egg production in layers, unthriftiness, ruffled feathers, decreased weight gain, emaciation with protrusion of keel bone (Fig. 1A) and in some cases; pigeon flies were observed on birds' body, under/or on the wings or on tail (Fig. 1B) and Fig. 2.

Most of the examined pigeons were positive with at least with one of external parasitic species. The overall prevalence rate was 80.3%.

3.2. External parasites

External parasites usually observed on living birds. In case of lice infestation, eggs were attached with feathers roots, while in

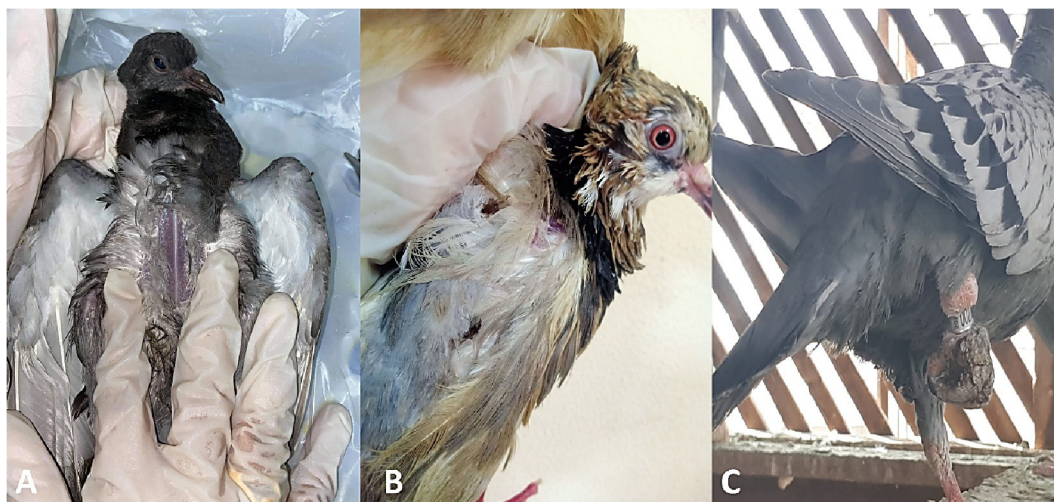


Fig. 1. A: Pigeon showing emaciation with ruffled feather; B: Pigeon showing ruffled feather with presence of *Pseudolynchia* flies on its body; C: Pigeon showing unilateral arthritis with presence of raised grayish color scales with grayish exudates in between scales on pigeon's shank.

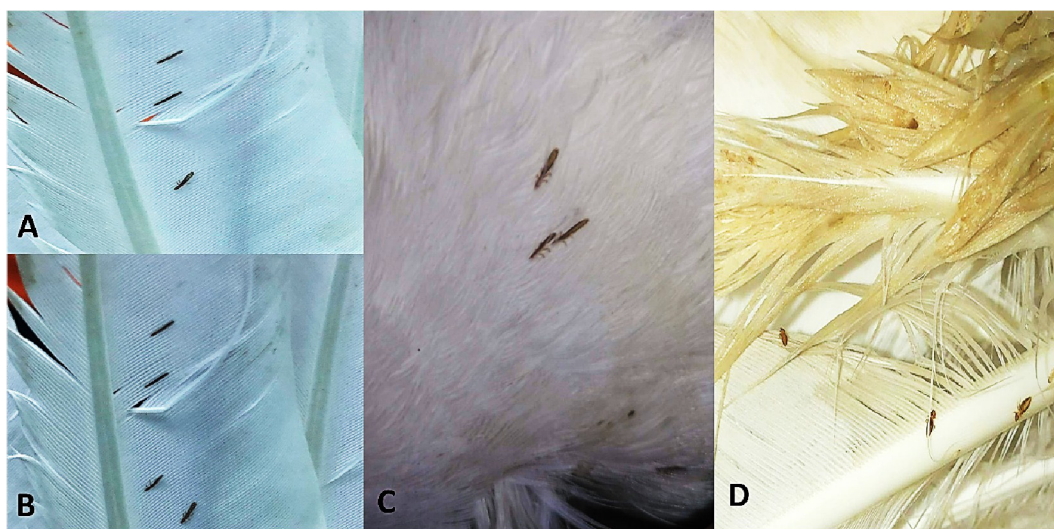


Fig. 2. A, B & C: Pigeon feathers showing attachment of *C. columbae*. D: Pigeon feathers showing attachment of *M. gallinae*.

red mite; the red spots were observed surround the bird vent, unilateral arthritis was observed in birds mange with presence of dull raised scales tinged with grayish to brown color exudate on shank of pigeon leg (Fig. 1C).

Two hundred and forty-one; out of 300 examined pigeons, were positive for external parasites infestations. Six different types of external parasites were detected as follow: *P. canariensis*, *H. equina*, *C. columbae*, *M. gallinae*, *Knemidocoptes* spp. and *D. gallinae* with prevalence 41.6, 26, 7, 5, 0.33 and 0.33%, respectively. The intensity of external parasites on pigeon's body were ranged from (1–6), (1–4), (8–25) and (5–20) in case of *P. canariensis*, *H. equina*, *C. columbae*, and *M. gallinae*, respectively.

The prevalence and intensity of ectoparasites in domestic pigeons based on their age were summarized in (Fig. 3 & Table 1) and Fig. 4.

Single infestation of pigeons with *P. canariensis*, *H. equina*, *C. columbae*, *M. gallinae*, *Knemidocoptes* spp. and *D. gallinae* were recorded also; mixed external parasites infestation between (*P. canariensis* and *H. equina*); (*P. canariensis* and *C. columbae*); (*C. columbae* and *M. gallinae*) and (*P. canariensis*; *C. columbae* and *M. gallinae*) were observed and summarized in; Table 2.

The highest prevalence of external parasites was detected in spring and summer seasons as seen in (Table 3).

Infested pigeon with *H. equina* showed significantly higher in Nitric oxide (120.56 ± 4.56 , $\pm 95\%$ C.I.) while in mixed infestation with *P. canariensis* it reaches to 145.89 ± 9.43 ; the Nitric oxide levels was low in *M. gallinae* reach to 56.89 ± 3.76 . Serum MDA reach to 100.30 ± 6.48 , 95% C.I.; in mixed infestation with *P. canariensis*, *H. equina*, while it was low in *C. columbae* infestation. zinc levels were decreased with parasitic infestation as it reaches to low levels in *P. canariensis*, *H. equina* mixed infestation; all data were compared to control levels of oxidative stress markers and zinc levels (Table 4).

Periodical, monthly usage of deltamethrin in the infested flocks revealed a marked decrease in external parasites numbers after two days of treatment with relieve of the clinical signs.

4. Discussion

Pigeons are a point of anxiety since they can spread zoonoses to humans and are a reservoir for numerous parasite diseases affecting poultry (Sari et al., 2008). Most of examined pigeons showed



Fig. 3. A: Adult *P. canariensis*. B: Microscopic appearance of *D. gallinae*.

Table.1
Prevalence and intensity of ectoparasites in domestic pigeons in Giza, Egypt from January 2020 to December 2020.

Parasites	Positive cases (%)	Parasite's intensity	Age		
			Squabs (80)	Young (100)	Adults (120)
<i>P. canariensis</i>	125 (41.6)	1–6	50 (62.5%)	65 (65%)	10 (8.33%)
<i>H. equina</i>	78 (26)	1–4	12 (15%)	22 (28%)	44 (36.6%)
<i>C. columbae</i>	21 (7)	8–25	10 (12.5%)	8 (8%)	3 (2.5%)
<i>M. gallinae</i>	15 (5)	5–20	6 (0.75%)	4 (4%)	5 (4.16%)
<i>D. gallinae</i>	1 (0.33)	–	0	0	1 (0.33%)
<i>Knemidocoptes</i> spp.	1(0.33)	–	0	0	1 (0.33%)
Total	241 (80.3%)	–	78/80(97.5%)	99/100 (99%)	63/120 (52.5%)




Fig. 4. A summarized diagram showing the prevalence of different external parasites of pigeons in Giza, Egypt from January 2020 to December 2020.

signs of ruffled feathers, severe emaciation. Similar signs were observed in case of parasitic infestation as recorded by Abd El-Rahman et al., (2008); Mohamed et al., (2009) and Abdel Rahman et al., (2019).

Ectoparasites live on feathers and skin of the host, using as a shelter and food provider, they also have a considerable negative influence on host health and productivity. From our results, the overall prevalence of external parasites was 80.3% (241/300) either

single or mixed infestations, six different arthropods species were identified as follow: *P. canariensis* (41.6%), *H. equina* (26%), *C. columbae* (7%), *M. gallinae* (5%), *D. gallinae* (0.33 %), and *Knemidocoptes* spp (0.33%). Higher prevalence 89% (89/100) was recorded in Tripoli, Libya by Alkharigy et al., (2018) as they found the prevalence of *C. columbae* (82%), *Goniodes gallinae* (18%), *M. gallinae* (3%) and *P. canariensis* (1%). Also, Radfar et al., (2011) recorded higher prevalence of external parasites in pigeon, *C. columbae* (79.41%), *M. gallinae* (44.11%) and *P. canariensis* (63.72%) in south khorasan; Iran while, in Colombia, Pérez-García et al., (2015) found that the prevalence of *C. columbae* (64%), *P. canariensis* (52%), *M. gallinae* (24%). Borji et al., (2012) reported that the prevalence of *C. columbae* (42.8%), *P. canariensis* (16.1%) and *M. gallinae* (7.1%) in Mashhad city Iran. Also, Ali et al., (2020) recorded two external parasites on (Harami) pigeons, including the shaft louse *M. gallinae* and *P. canariensis* with 100 and 88.90% prevalence, respectively in Medina, Saudi Arabia.

In another study, the incidence of *H. equina* was 26% while Sokół and Michalski, (2015) noticed the low host specificity of *H. equina* which could attack cattle, dogs, hares, birds, and humans.

The prevalence of *C. columbae* was 21% however, Jahantigh et al., (2016), Dranzo et al., (1999) and Foronda et al., (2004) recorded higher prevalence of *C. columbae* 78.40%, 94.1 and 100% in Iran, Uganda, and Tenerife, respectively.

From our findings, *Knemidocoptes* spp. was observed in one case only with incidence of 0.33% during summer season and its lesion was found as unilateral arthritis and presence of severe dermatitis that appeared as raised dull color scales with presence of grayish color exudate between scales. Similar findings were observed in

Table.2
Prevalence of single and mixed infestation of external parasites in domestic pigeons.

Parasite	Type of infestation	Prevalence (Positive cases/300 total examined birds)	
		No.	%
<i>P. canariensis</i>	Single	90	30
<i>H. equina</i>		66	22
<i>C. columbae</i>		9	3
<i>M. gallinae</i>		3	1
<i>D. gallinae</i>		1	0.33
<i>Knemidocoptes</i> spp.	mixed	1	0.33
<i>P. canariensis</i> + <i>H. equina</i>		22	7.33
<i>P. canariensis</i> + <i>C. columbae</i>		31	10.33
<i>C. columbae</i> + <i>M. gallinae</i>		12	4
<i>P. canariensis</i> + <i>C. columbae</i> + <i>M. gallinae</i>		6	2
Total No. of positive pigeons		241	80.3

Table.3
Seasonal prevalence of external and internal parasites in domestic pigeons.

External Parasite	Spring		Summer		Autumn		Winter	
	No.	%	No.	%	No.	%	No.	%
<i>Pseudolynchia canariensis</i>	57	76	60	80	5	6.66	3	4
<i>Hippobosca equina</i>	18	24	48	66.6	12	16	0	0
<i>Columbicola columbae</i>	8	10.66	10	13.33	2	2.66	1	1.33
<i>Menopon gallinae</i>	6	8	9	12	0	0	0	0
<i>Dermanyssus gallinae</i>	0	0	1	1.33	0	0	0	0
<i>Knemidocoptes</i> spp.	0	0	1	1.33	0	0	0	0

No. = number of positive cases.

Table.4
Oxidative stress markers in relation to single and mixed infection of external parasites.

Parasite	Oxidative stress markers		
	Nitric oxide	MDA serum	Zinc
<i>P. canariensis</i>	95.57 ± 3.67	78.38 ± 5.17	54.04 ± 2.85
<i>H. equina</i>	120.56 ± 4.56	88.38 ± 4.49	36.77 ± 1.32
<i>C. columbae</i>	67.98 ± 7.00	30.33 ± 3.35	100.24 ± 1.00
<i>M. gallinae</i>	56.89 ± 3.76	33.56 ± 3.46	110.52 ± 2.96
<i>D. gallinae</i>	79.89 ± 5.99	50.33 ± 1.03	33.57 ± 2.82
<i>Knemidocoptes</i> spp.	80.14 ± 6.33	52.35 ± 1.67	34.66 ± 3.62
<i>P. canariensis</i> + <i>H. equina</i>	145.89 ± 9.43	100.30 ± 6.48	28.89 ± 1.52
<i>P. canariensis</i> + <i>C. columbae</i>	110.00 ± 3.59	98.33 ± 2.45	59.97 ± 3.95
<i>C. columbae</i> + <i>M. gallinae</i>	74.49 ± 9.32	60.38 ± 2.98	100.67 ± 2.96
<i>P. canariensis</i> + <i>C. columbae</i> + <i>M. gallinae</i>	160.84 ± 3.57	98.89 ± 2.78	34.56 ± 2.96
Control	49.78 ± 0.95	27.89 ± 0.69	118.00 ± 0.94

a parallel study conducted by [Abou-Alsoud and Karrouf, \(2016\)](#) who detected *Knemidocoptes Pilae* with prevalence of (11.5 %) in Budgerigars in Mansoura public park, Egypt.

The mixed infestation was reported as follow: *P. canariensis* + *H. equina* with prevalence 7.33%. *P. canariensis* + *C. columbae* with 10.33 % prevalence; *C. columbae* + *M. gallinae* (4%) and *P. canariensis* + *C. columbae* + *M. gallinae* (2%). Also, [Alkharigy et al., \(2018\)](#) recorded mixed infestation with external parasites in Libya. The mixed infestation of pigeon with external parasites could be contributed to that ectoparasites can live together without causing any hurtful effects on each other ([Radfar et al., 2011](#)).

The occurrence of ectoparasitic infestations in squabs (82.5%) was higher than young (77%) and lowest prevalence was recorded in adults (18%). Same observations were recorded by [da Cunha Amaral et al., \(2013\)](#) in case of *P. canariensis* infestation but, [Msoffe et al., \(2010\)](#) and [Radfar et al., \(2012\)](#) noticed that the prevalence of *P. canariensis* were higher in adult pigeons than squabs. Adult pigeons are predicted to have a lower incidence of ectoparasites since they have a higher level of parasite immunity

([Merila et al.,1995](#)) and adult birds use their claws and the bill to get rid of ectoparasites ([Clayton et al., 2010](#); [Waite et al., 2012](#)).

From our results, the intensity (number of external parasites that are found per bird) of external parasites on pigeon’s body ranged from (1:6), (1:4), (8:25) and (5:20) in case of *P. canariensis*, *H. equina*, *C. columbae* and *M. gallinae*, respectively. This result is agreed with [Attia and Salem \(2021\)](#) as they noticed that the intensity of *P. canariensis* flies was 1: 6 (2.00 ± 1.0) on pigeons’ body in El- Gharbia, Egypt.

The ambient temperature is the key determinant of the frequency, quantity, and diversity of external parasites all over year ([Al-Barwari and Saeed 2012](#); [Attia et al. 2017](#)). In our study the highest prevalence of external parasites infestations was recorded in both spring and summer. The prevalence of *P. canariensis* was 76% and 80%, *C. columbae* was 10.66% and 13.33%, *M. gallinae* was 8 % and 12% in spring and summer, respectively. *D. gallinae* only detected in summer season only 1.33%. The lowest prevalence of external parasites infestation in our study was recorded in autumn and winter season, *P. canariensis* was 6.66% and 4%, *C. columbae* was 2.66% and 1.33% in autumn and winter, respectively, on the other hand, no positive cases of *M. gallinae* and *D. gallinae* were recorded in autumn and winter. The differences in the seasonal prevalence may be contributed to the ambient temperature in Egypt exceed 25 C° in both spring and summer which considered a favorable condition for insects’ population.

Continuous exposure of poultry to ectoparasites that act as intermediate hosts for different parasitic worms increases the potential for the spread of parasitic diseases among birds ([Ashenafi and Eshetu, 2004](#)). So, monthly spray of deltamethrin is recommended and provoke acceptable result and succeeded in limitation of external parasites load. This result is agreed with ([Attia and Salem, 2021](#)) as they found deltamethrin is effective in *P. canariensis* control. Deltamethrin has proven its efficiency in controlling insects and we recommend in the future to load the active substance on biological nanoparticles to increase its efficiency.

Also, recommend the use of some additives on pigeon food and drink as prebiotics (Abd El-Hack et al., 2021b; Yaqoob et al., 2021) probiotics (Abd El-Hack et al., 2021; Alagawany et al., 2021a; El-Saadony et al., 2021a), bioactive plants compounds (El-Saadony et al., 2021b), bioactive peptides (El-Saadony et al., 2021c,e), green synthesized nanoparticles (El-Saadony et al., 2021d,f), herbal extracts (Reda et al., 2021; Abou-Kassem et al., 2021), phytogetic compounds (Abd El-Hack et al., 2021c; Ashour et al., 2020), and essential oils (Alagawany et al., 2021b; El-Tarabily et al., 2021; Abd El-Hack et al., 2020) to strengthen their immune system and increase disease resistance.

The oxidative stress markers as (Nitric oxide and MDA levels) were raised in parasitic infestation either in single parasites or in mixed infestation due to rapid erythrocyte destruction and secretion of oxygen radicals (Mousa and Soliman, 2016); as recorded by Nazifi et al., (2011) and Razavi et al., (2011) found that the antioxidant enzyme activity of superoxide dismutase (SOD), glutathione peroxidase (GPX), and catalase, were raised during parasitic infestation.

5. Conclusion

When we spoke with pigeon owners, we discovered that most of them were unaware of dealing with a parasitic infestation in domestic pigeons, and some of them do not remedy them at all. From our findings, pigeons have a significant prevalence of external parasites, with single or mixed infestation. Oxidative stress markers were significantly elevated during either single or mixed external parasites infestations. Pathogenicity studies, regular monitoring, treatment, and control strategies must be put in place to reduce pigeon parasitic infestation considering that these birds are in close contact with other poultry and human. Deltamethrin could be considered as an effective insecticide for controlling of external parasites in the pigeon and would be recommended for regular use hand by hand with biosecurity measures.

Declaration of Competing Interest

The authors declare that they have no known competing financial interests or personal relationships that could have appeared to influence the work reported in this paper.

Acknowledgement

The current work was funded by Taif University Researchers Supporting Project number (TURSP - 2020/221), Taif University, Taif, Saudi Arabia.

References

- Abd El-Hack, M.E., El-Saadony, M.T., Swelum, A.A., Arif, M., Abo Ghanima, M.M., Shukry, M., El-Tarabily, K.A., 2021c. Curcumin, the active substance of turmeric: its effects on health and ways to improve its bioavailability. *J. Sci. Food Agric. in press*.
- Abd El-Hack, M.E., Alaidaroos, B.A., Farsi, R.M., Abou-Kassem, D.E., El-Saadony, M.T., Ashour, E.A., 2021. Impacts of supplementing broiler diets with biological curcumin, zinc nanoparticles and *Bacillus licheniformis* on growth, carcass traits, blood indices, meat quality and cecal microbial load. *Animals* 11 (7), 1878.
- Abd El-Hack, M.E., El-Saadony, M.T., Shafi, M.E., Alshahrani, O.A., Saghir, S.A., Al-Wajeeh, A.S., Al-Shargi, O.Y., Taha, A.E., Mesalam, N.M., Abdel-Moneim, A.-M.-E., 2021b. Prebiotics can restrict *Salmonella* populations in poultry: a review. *Anim. Biotechnol.* 19, 1–10.
- Abd El-Hack, M.E., El-Saadony, M.T., Shehata, A.M., Arif, M., Paswan, V.K., Batiha, G.-E.-S., Khafaga, A.F., Elbestawy, A.R., 2020. Approaches to prevent and control *Campylobacter* spp. colonization in broiler chickens: a review. *Environ. Sci. Pollut. Res.* 28 (5), 4989–5004.
- Abd El-Rahman, M.A.M., Seddiek, S.A., Soliman, A.S., 2008. Some studies on trichomoniasis of pigeons at Qualiobia governorate. *Egypt. J. Comp. Pathol. Clin. Pathol.* 21 (2), 123–141 <http://erepository.cu.edu.eg/index.php/EJCPCP/article/view/177>.
- Abdel Rahman, M.M.I.A., Tolba, H.M.N., Abdel-Ghany, H.M., 2019. Ultrastructure, morphological differentiation, and pathological changes of *Ascaridia* species in pigeons. *Adv. Anim. Vet. Sci.* 7 (2), 66–72. <https://doi.org/10.17582/journal.aavs/2019/7.2.66.72>.
- Abou-Asoud, M.E., Karrouf, G., 2016. Diagnosis and Management of *Knemidocoptes Pilae* in Budgerigars (*Melopsittacus Undulates*): Case Reports in Egypt. *M J Vete.* 1 (1), 007.
- Abou-Kassem, D.E., Mahrose, K.M., El-Samahy, R.A., Shafi, M.E., El-Saadony, M.T., Abd El-Hack, M.E., Emam, M., El-Sharnoubi, M., Taha, A.E., Ashour, E.A., 2021. Influences of dietary herbal blend and feed restriction on growth, carcass characteristics and gut microbiota of growing rabbits. *Ital. J. Anim. Sci.* 20, 896–910.
- Aktas, M.S., Kandemir, F.M., Kirbas, A., Hanedan, B., Aydin, M.A., 2017. Evaluation of oxidative stress in pigeon infected with *Psoroptes ovis* using total antioxidant capacity, total oxidant status, and malondialdehyde level. *Vet. Res.* 61(2):197–201. <https://doi.org/10.1515/jvetres-2017-0025>.
- Alagawany, M., El-Saadony, M., Elnesr, S., Farahat, M., Attia, G., Madkour, M., Reda, F., 2021a. Use of lemongrass essential oil as a feed additive in quail's nutrition: its effect on growth, carcass, blood biochemistry, antioxidant and immunological indices, digestive enzymes and intestinal microbiota. *Poult. Sci.* 100, (6) 101172.
- Alagawany, M., Madkour, M., El-Saadony, M.T., Reda, F.M., 2021b. *Paenibacillus polymyxa* (LM31) as a new feed additive: Antioxidant and antimicrobial activity and its effects on growth, blood biochemistry, and intestinal bacterial populations of growing Japanese quail. *Anim. Feed Sci. Technol.* 276, 114920.
- Al-Barwari, S.H., Saeed, I., 2012. The Parasitic Communities of the rock pigeon *Columba livia* from Iraq: Component and Importance. *Turkiye Parazitol Derg* 36, 232–239. <https://doi.org/10.5152/tpd.2012>.
- Ali, M., Ibrahim, R., Alahmadi, S., Elshazly, H., 2020. Ectoparasites and intestinal helminths of pigeons in Medina, Saudi Arabia. *J Parasitol.* 12, 106(6):721–729. <https://doi.org/10.1645/20-64>. DOI: 10.1645/20-64.
- Alkharigiy, F.A., El Naas, A.S., El Maghrbi, A.A., 2018. Survey of parasites in domestic pigeons (*Columba livia*) in Tripoli, Libya. *Open Vet. J.* 8(4): 360–366. <http://dx.doi.org/10.4314/ovj.v8i4>.
- Ashenafi, H., Eshutu, Y., 2004. Study on Gastro-intestinal helminths of local chickens in Central Ethiopia. *Rev. Med. Vet.* 155(10): 504–507. https://www.revmedvet.com/RMV155_504_507.
- Ashour, E.A., El-Hack, M.E.A., Shafi, M.E., Alghamdi, W.Y., Taha, A.E., Swelum, A.A., Tufarelli, V., Mulla, Z.S., El-Ghareeb, W.R., El-Saadony, M.T., 2020. Impacts of green coffee powder supplementation on growth performance, carcass characteristics, blood indices, meat quality and gut microbial load in broilers. *Agriculture* 10, 457.
- Atkinson, C.T., Thomas, N.J., Hunter, D.B., 2008. Parasitic diseases of wild birds. John Wiley & Sons, Inc. ISBN: 978-0-813-82081-1. U.S. Library of Congress. <https://doi.org/10.1002/9780813804620>.
- Attia, M.M., El-Gameel, S.M., Ismael, E., 2020. Evaluation of tumor necrosis factor-alpha (TNF- α), gamma interferon (IFN- γ) genes and oxidative stress in sheep: immunological responses induced by *Oestrus ovis* (Diptera: Oestridae) infestation. *J. Parasit. Dis.* 44(2): 332–337. <https://doi.org/10.1007/s12639-020-01220-w>.
- Attia, M.M., Salem, H.M., 2021. Morphological and molecular characterization of *Pseudolynchia canariensis* (Diptera: Hippoboscidae) infesting domestic pigeons. *Int. J. Trop. Insect Sci.* <https://doi.org/10.1007/s42690-021-00597-2>.
- Attia, M.M., Soliman, S.M., Khalif, M.A., 2017. Hydrophilic nanosilica as a new larvicidal and molluscicidal agent for controlling of major infectious diseases in Egypt. *Vet World.* 10 (9), 1046–1051.
- Aytekin, I., Unubol Aypak, S., 2011. Levels of selected minerals, nitric oxide, and vitamins in aborted Sakis pigeon raised under semitropical conditions. *Trop. Anim. Health Prod.* 43:511–514. <https://doi.org/10.1007/s11250-010-9724-x>.
- Badparva, E., Ezatpour, B., Azami, M., Badparva, M., 2015. First report of bird's infection by intestinal parasites in Khorramabad, west Iran. *J. Parasit. Dis.* 39 (4), 720–724. <https://doi.org/10.1007/s12639-014-0427-5>.
- Beadell, J.S., Ishfaq, F., Covas, R., Melo, M., Warren, B.H., Atkinson, C.T., Bensch, S., Graves, G.R., Jhala, Y.V., Peirce, M.A., Rahmani, A.R., Fonseca, D.M., Fleischer, R.C., 2006. Global phylogeographic limits of Hawaii's avian malaria. *Proc R Soc Lond. Series B.* 273 (2935–2944). <https://doi.org/10.1098/rspb.2006.3671>.
- Borji, H., Moghaddas, E., Razmi, G.R., Azad, M., 2012. A survey of ecto- and endoparasites of domestic pigeons (*Columba livia*) in Mashhad, Iran. *J. Vet. Sci. Technol.* 4(2):37–42. <https://doi.org/10.4314/ovj.v8i4.2>.
- Clayton, D.H., Koo, J., Harbiso, C., Moye, B., Bush, S., 2010. How birds combat ectoparasites. *J. Ornithol.* 3: 41–71. <https://doi.org/10.2174/1874453201003010041>.
- da Cunha Amarala, H., Bergmann, F.B., Silveira, T., Silveira dos Santos, P.R., Krüger, R.F., 2013. *Pseudolynchia canariensis* (Diptera: Hippoboscidae): distribution pattern and phoretic association with skin mites and chewing lice of *Columba livia* (Aves: Columbidae). *J. Nat. Hist.* 47 (47–48), 2927–2936. <https://doi.org/10.1080/00222933.2013.791939>.
- Dranzoa, C., Ocáido, M., Katete, P., 1999. The ecto-gastro-intestinal and haemoparasites of live pigeons (*Columba livia*) in Kampala, Uganda. *Avian Pathol.* 28, 119–124. <https://doi.org/10.1080/03079459994830>.
- Eladi, A., Hamed, H.R., El-Shafei, R.A., 2018. Prevalence of mites and their impact on laying hen (*Gallus gallus domesticus*) farm facilities in Egypt, with an analysis of deltamethrin residues in eggs and tissue. *Avian Pathol.* 47 (2), 161–171. <https://doi.org/10.1080/03079457.2017.1388500>.

- El-Dakhly, K., Mahrous, L.N., Mabrou, G.A., 2016. Distribution pattern of intestinal helminths in domestic pigeons (*Columba livia domestica*) and turkeys (*Meleagris gallopavo*) in Beni-Suef province Egypt. *J. Vet. Med. Res.* 23(1):112–120. <https://doi.org/10.21608/JVMR.2016.43226>.
- El-Saadony, M.T., Alagawany, M., Patra, A.K., Kar, I., Tiwari, R., Dawood, M.A., Abdel-Latif, H.M., 2021a. The functionality of probiotics in aquaculture: An overview. *Fish Shellfish Immunol.* 117, 36–52.
- El-Saadony, M.T., Zabermaawi, N.M., Zabermaawi, N.M., Burollus, M.A., Shafi, M.E., Alagawany, M., Abd El-Hack, M.E., 2021b. Nutritional aspects and health benefits of bioactive plant compounds against infectious diseases: A review. *Food Rev. Int.*, 1–23.
- El-Saadony, M.T., Abd El-Hack, M.E., Swelum, A.A., Al-Sultan, Sa.ad., El-Ghareeb, W. R., Hussein, E.O.S., Ba-Awadh, H.A., Akl, B.A., Nader, M.M., 2021c. Enhancing quality and safety of raw buffalo meat using the bioactive peptides of pea and red kidney bean under refrigeration conditions. *Ital. J. Anim. Sci.* 20 (1), 762–776.
- El-Saadony, M.T., Alkhatib, F.M., Alzahrani, S.O., Shafi, M.E., Abdel-Hamid, S.E., Taha, T.F., Aboelenin, S.M., Soliman, M.M., Ahmed, N.H., 2021d. Impact of mycogenic zinc nanoparticles on performance, behavior, immune response, and microbial load in *Oreochromis niloticus*. *Saudi J. Biol. Sci.* 28 (8), 4592–4604.
- El-Saadony, M.T., Khalil, O.S., Osman, A., Alshilawi, M.S., Taha, A.E., Aboelenin, S.M., Shukry, M., Saad, A.M., 2021e. Bioactive peptides supplemented raw buffalo milk: biological activity, shelf life and quality properties during cold preservation. *Saudi J. Biol. Sci.* 28 (8), 4581–4591.
- El-Saadony, M.T., Saad, A.M., Najjar, A.A., Alzahrani, S.O., Alkhatib, F.M., Shafi, M.E., Selem, E., Desoky, E.-S.M., Fouada, S.E.-S.E.-S., El-Tahan, A.M., 2021f. The use of biological selenium nanoparticles in controlling *Triticum aestivum* L. crown root and rot diseases induced by *Fusarium* species and improve yield under drought and heat stress. *Saudi J. Biol. Sci.* 28 (8), 4461–4471.
- El-Tarabily, K.A., El-Saadony, M.T., Alagawany, M., Arif, M., Batiha, G.E., Khafaga, A.F., Elwan, H.A., Elnesr, S.S., Abd El-Hack, M.E., 2021. Using essential oils to overcome bacterial biofilm formation and their antimicrobial resistance. *Saudi J. Biol. Sci.* 28 (9), 5145–5156.
- Elyazar, I. R.F., Hay, S. I., Baird, J. K., 2011. Chapter 2 - Malaria distribution, prevalence, drug resistance and control in Indonesia. *ADV PARASIT.* 74: 41–175. <https://doi.org/10.1016/B978-0-12-385897-9.00002-1>.
- Foronda, P., Valladares, B., Rivera-Medina, J.A., 2004. Parasites of *Columba livia* (Aves: Columbiformes) in Tenerife (Canary Islands) and their role in the conservation biology of the Laurel pigeons. *Parasite.* 1: 311–316. <https://doi.org/10.1051/parasite/2004113311>.
- Hussein, N.M., Abdelrahim, E.A., 2016. *Haemoproteus Columbae* infection and its histopathological effects on pigeons in Qena Governorate, Egypt. *IOSR-JPBS.* 11 (1): 79–90. <https://doi.org/10.9790/3008-11117990>.
- Imura, T., Suzuki, Y., Ejiri, H., Sato, Y., Ishida, K., Sumiyama, D., Murata, K., Yukawa, M., 2012. Prevalence of avian haematzoa in wild birds in a high-altitude forest in Japan. *Vet. Parasitol.* 183: 244–248. <https://doi.org/10.1016/j.vetpar.2011.07.027>.
- Jahantigh, M., Esmailzade Dizaji, R., Teymoori, Y., 2016. Prevalence of external parasites of pigeon in Zabol, southeast of Iran. *J. Parasit. Dis.* 40(4):1548–1551. <https://doi.org/10.1007/s12639-015-0725-6>.
- Khazaei, M., Nematbakhsh, M., 2012. Effect of experimentally induced metabolic acidosis on aortic endothelial permeability and serum nitric oxide concentration in normal and high-cholesterol fed rabbits. *Arch. Med. Sci.* 8 (4), 719–723. <https://doi.org/10.5114/aoms.2012.30296>.
- Martinsen, E.S., Paperna, I., Schall, J., 2006. Morphological versus molecular identification of avian Haemosporidia: an exploration of three species concepts. *Parasitol.* 13(3):279–288. <https://doi.org/10.1017/S0031182006000424>.
- Merila, J., Bjorklund, M., Bennett, G.F., 1995. Geographic and individual variation in haematzoan infections in the greenfinch, *Carduelis chloris*. *Can. J. Zool.* 73:1798–1804. <https://doi.org/10.1139/z95-212>.
- Mohamed, I.E., El-Sakkar, G.H., Moursi, M.M., 2009. Pathological studies on pigeon trichomoniasis with reference to the associated bacteria. *J. Comp. Pathol. Clin. Pathol.* 22 (2), 67–87. http://www.pathologyeg.com/publication2009_2/Publication3.pdf.
- Mousa, S.A., Soliman, S.M., 2016. Oxidant and Antioxidant Status in Pneumonic Goats with Special Reference to Bacterial Etiology. *Int. J. Livestock Res.* 6 (5), 15–23. <https://doi.org/10.5455/ijlr.20160417045508>.
- Msoffe, P.L.M., Muhairwa, A.P., Chiwanga, G.H., Kassuku, A.A., 2010. A study of ecto- and endo-parasites of domestic pigeons in Morogoro unicity. *Tanzania. Afr. J. Agric. Res.* 5 (3), 264–267.
- Nazifi, S., Razavi, S.M., Kiani Amin, P., Rakhshandehroo, E., 2011. Evaluation of erythrocyte antioxidant mechanisms: antioxidant enzymes, lipid peroxidation and serum trace elements associated with progressive anemia in ovine malignant theileriosis. *Parasitol. Res.* 109 (275–281). <https://doi.org/10.1007/s00436-010-2248-5>.
- Page, C.M., Murphy, T.W., Van, M.L., Emon, J.G., Bowman, P., Wyffels, S.A., Stewart, W.C., 2018. Blood serum mineral element concentrations of weaned Montana ram lambs and their relationship with water quality characteristics. *Prof. Anim. Sci.* 34 (5), 410–420. <https://doi.org/10.15232/pas.2018-01747>.
- Pérez-García, J., Monsalve-Arcila, D., Márquez-Villegas, C., 2015. Presencia de parásitos y enterobacterias en palomas ferales (*Columba livia*) en áreas urbanas en Envigado Colombia. *Rev. Fac. Na.c Salud Pública.* 33 (3), 370–376.
- Radfar, M.H., Asl, E.N., Seghinsara, H.R., Dehaghi, M.M., Faith, S., 2012. Biodiversity and prevalence of parasites of domestic pigeons (*Columba livia domestica*) in a selected semi-arid zone of South Khorasan, Iran. *TROP. ANIM. HEALTH PRO.* 44 (2):225–229. <https://doi.org/10.1007/s11250-011-0002-3>.
- Radfar, M.H., Fathi, S., Asl, E.N., Dehaghi, M.M., Seghinsara, H.R., 2011. A survey of parasites of domestic pigeons (*Columba livia domestica*) in South Khorasan, Iran. *J. Vet. Res.* 4(1):18–23. <https://doi.org/10.3923/vr.2011.18.23>.
- Razavi, S., Nazifi, S., Bateni, M., Rakhshandehroo, E., 2011. Alterations of erythrocyte antioxidant mechanisms: antioxidant enzymes, lipid peroxidation and serum trace elements associated with anemia in bovine tropical theileriosis. *Vet. Parasitol.* 180(3):209–214. <https://doi.org/10.1016/j.vetpar.2011.03.011>.
- Reda, F., El-Saadony, M., El-Rayes, T., Farahat, M., Attia, G., Alagawany, M., 2021. Dietary effect of licorice (*Glycyrrhiza glabra*) on quail performance, carcass, blood metabolites and intestinal microbiota. *Poult. Sci.* 100, (1) 101266.
- Salem, M.H., Attia, M.M., 2021. Accidental intestinal myiasis caused by *Musca domestica* L. (Diptera: Muscidae) larvae in broiler chickens: a field study. *Int. J. Trop. Insect. Sci.* <https://doi.org/10.1007/s42690-021-00492-w>.
- Sari, B., Karatepe, B., Karatepe, M., Kara, M., 2008. parasites of domestic (*Columba livia domestica*) and wild (*Columba livia livia*) pigeons in niğde, turkey. *Bull. Vet. Inst. Pulawy.* 52 (4), 551–554.
- Sokół, R., Michalski, M.M., 2015. Occurrence of *Hippobosca equina* in Polish primitive horses during the grazing season. *Ann. Parasitol.* 61 (2), 118–122.
- Soulsby, E.J.L., 1986. *Helminths, Arthropods and Protozoa of Domesticated Animals*. Bailliere Tindall, London, pp. 167–174.
- Swinnerton, K.J., Peirce, M.A., Greenwood, A., Chapman, R.E., Jones, C.G., 2005. Prevalence of *Leucocytozoon marchouxi* in the endangered Pink Pigeon *Columba mayeri*. *Ibis.* 147(4):725–737. <https://doi.org/10.1111/j.1474-919X.2005.00454.x>
- Waite, J.L., Henry, A.R., Clayton, D.H., 2012. How effective is preening against mobile ectoparasites? An experimental test with pigeons and hippoboscids flies. *Int. J. Parasitol.* 42(5):463–467. <https://doi.org/10.1016/j.ijpara.2012.03.005>.
- Yaqoob, M., Abd El-Hack, M., Hassan, F., El-Saadony, M., Khafaga, A., Batiha, G., Yehia, N., Elnesr, S., Alagawany, M., El-Tarabily, K., 2021. The potential mechanistic insights and future implications for the effect of prebiotics on poultry performance, gut microbiome, and intestinal morphology. *Poult. Sci.* 100, (7) 101143.