

Notes on the Ultrastructure of Chewing Lice (*Columbicola columbae*, Linnaeus, 1758 (Ansari 1947) Infesting Domestic Pigeon (*Columba livia*)

Souad M. Al-Saqabi

Biology Department, College of Sciences and Arts in Unizah, Qassim University –Al-Qassim -Saudi Arabia

Email: [salsaqabi3\[at\]gmail.com](mailto:salsaqabi3[at]gmail.com)

Abstract: Pigeons (*Columba livia*) are economically important because they are a key food source of protein for humans. Chewing lice are external parasites and are most commonly found on birds, especially pigeons, due to infection, but not considered a disease. Instead, the phenomenon results from their transmission through contact with other infected birds or negligence in caring for birds and controlling lice using pesticides. This study aimed to use scanning electron microscopy to determine the exact structure of chewing lice (*Columbicola columbae*, Linnaeus, 1758 (Ansari 1947)), which infect *Columba livia* pigeons, a species that is locally bred in the eastern region. Forty samples of 6-month-old male and female pigeons were collected. The results showed that the pigeons were infected with a species of chewing lice and also clarified the precise structure of the chewing lice. This study revealed that the number of sensory bristles at the end of the antenna should be used as a classifier to identify species. This is the first study on chewing lice in Saudi Arabia. Infection with chewing lice causes wounds and feather breakage and fall off; in addition, it causes a lack of rest in the pigeons, which stunts their growth. It is necessary to develop a successful plan to prevent and control chewing lice. Moreover, it is necessary to identify the factors that will help increase breeders' awareness of resistance.

Keywords: *Columba livia*, Ectoparasites, Pigeon, Classification, Structure, Saudi Arabia

1. Introduction

Pigeons (*Columba livia*) are economically important because they are considered a food source. They are also regarded as responsible for common human and animal diseases, such as bird flu (Piasecki, 2006); moreover, they cause contamination of surrounding areas through their waste. In Saudi Arabia, pigeons are kept mainly for sale or by amateur pigeon breeders. However, pigeons may be infected with many organisms, serving as a reservoir for parasitic poultry diseases; contact with pigeons with other domestic birds increases parasite infection risk in birds (Piasecki, 2006 and Sari et al., 2008).

External parasites play an essential role in transmitting many diseases. The presence of chewing lice on pigeons is evidence of inadequate care. One of the critical ectoparasites that affect pigeons is chewing lice, which live on the outer bodies of the pigeons. The lice do not consume blood but live on the remnants of feathers. Once a pigeon is infected, the parasite breeds rapidly. Currently, chewing lice are not known to transmit diseases to pigeons. Instead, they produce many eggs on the feathers, causing slight irritation and the disappearance of healthy feathers in cases of significant infection. Therefore, a change in pigeons' behavior can indicate a louse infestation, although the lice cannot be seen. When pigeons have lice, they may puff up their feathers and act agitated; moreover, weight loss will be noticeable (Fatihu et al., 1991).

Some studies have recorded that the fall of feathers is linked to lice and is associated with other diseases, such as coccidiosis, internal worms, nematodes, and bacterial infections. It is also possible to detect chewing louse infection if changes in the pigeons' behavior, infections,

feather inflation, ease of movement, and weight loss are noted (Fatihu et al., 1991).

The study of parasites in pigeons will contribute to improving the health of these birds. Several studies have been conducted on parasitic diseases of pigeons in many countries worldwide. In Nigeria, researchers found that pigeons are usually infested with chewing lice, such as *Menopon gallinae*, *Columbicola columbae*, and *Pseudolynchia canariensis* (Adang et al., 2008).

However, other studies conducted in the Kingdom of Saudi Arabia on sparrows recorded the highest infestation rates of ectoparasites (Abdelmageed et al., 2018). Two chewing louse infestations of seabirds on Humor Island in the Farasan Archipelago of Saudi Arabia were recorded. The species were *Actornithophilus areolae* from suborder Amblycera and *Quadriceps brunneus* from suborder Ischnocera (Alahmed et al., 2012). Amblyceran and Ischnoceran lice removed from Indian peafowl (*Pavo cristatus* L.) were collected at the Riyadh bird market. *Goniodes dissimilis* was found to infest this bird species for the first time, along with *Menacanthus stramineus* (Nasser et al., 2015b). The Arabian partridge *Alectoris melanocephala* and Philby's partridge *Alectoris philbyi* are two endemic species distributed through the Sarawat Mountains in Saudi Arabia and Yemen. Only one rare species of chewing louse, *Cuculotogaster arabicus*, was found to infest these birds, which is considered the first record from Saudi Arabia (Nasser et al., 2016).

One of the most important studies that showed the precise structure of chewing lice affecting pigeons was a study on pigeons' hatching and behavior that identified the chewing louse *C. columbae*, with images captured by scanning

electron microscopy. However, the ultra structure of these lice was not described (Singh et al., 2010).

This study aimed to study the ultra structure of the chewing louse *C.columbae*, as it has not been previously characterized by scanning electron microscopy. The most important way to identify a parasitic species in any infected host is to conduct morphological studies. Therefore, it is essential to study this infection in birds to supplement the sources that provide information about this region's species.

2. Materials and Methods

This study was performed in 2019 for six months in the eastern province (Dammam .26°24'54.6"N, 50°01'43.6"E) of Saudi Arabia. Specifically, forty pigeons belonging to *C. columbae* were examined for chewing lice. The lice were collected, and each bird's body was examined carefully by covering the body with plastic bags, leaving the head outside of the bag. The pigeon's body was then exposed to an insecticide (Sevin 85) to kill any lice, allowing their collection without affecting the birds and without choking them.

The collected louse specimens were divided into two portions: one for light microscopy (80 samples on slides) and the other for scanning electron microscopy (20 samples for examination). All lice were collected and placed in tubes with 70% alcohol.

1) Preparation for light microscopy:

The chewing louse specimens were cleared for approximately 24 hours in 10% KOH and then placed in distilled water for one day. Following dehydration in a graded alcohol series (70%, 80%, 90%, and 99%, on consecutive days), the specimens were mounted on slides in Canada balsam (Soulsby, 1982). After being dried in an incubator, the louse specimens were identified under a light

microscope. A stereoscopic microscope (Olympus Stereomicroscope (SZX7)) and a novel microscope were used. Images were captured with a USB digital microscope mount adapter. The identification of the lice was carried out according to the relevant literature (Soulsby, 1982, Price et al., 2003, Adams et al., 2005, Gustafsson et al., 2015).

2) Preparing specimens for Scanning Electron Microscopy (SEM)

- Specimens (20 males and females) of chewing lice in 70% fixative were removed and immersed immediately in 4F1G (fixative, phosphate buffer solution; pH=7.4) at 4°C for 3 hours.
- The specimens were then postfixed in 2% OsO₄ in the same buffer at 4°C for 2 hours.
- The samples were washed in buffer and dehydrated at 4°C through a graded series of ethanol.
- Samples of chewing lice were dried utilizing a critical point method and mounted using carbon paste on an aluminum stub and coating unit (JFC-1100E).
- Observations of chewing louse morphology were performed for the coded specimens with JEOL-JSM-5300 and JEOLJSM_IT200 scanning electron microscopes operated between 15 and 20 keV (Turner et al., 2002, Tahmasebi et al., 2015).

3. Results

The study conducted over 6 months on *Columba livia* showed that they were infested with *Columbicola columbae*, with an incidence rate of 95%, as shown in Table 1 and Figure 1.

Table 1: Comparison percentages of count lice that infected pigeon

Total number 40	Infected	%	Account infected	%
<i>C.columbae</i>	38	95	2	5

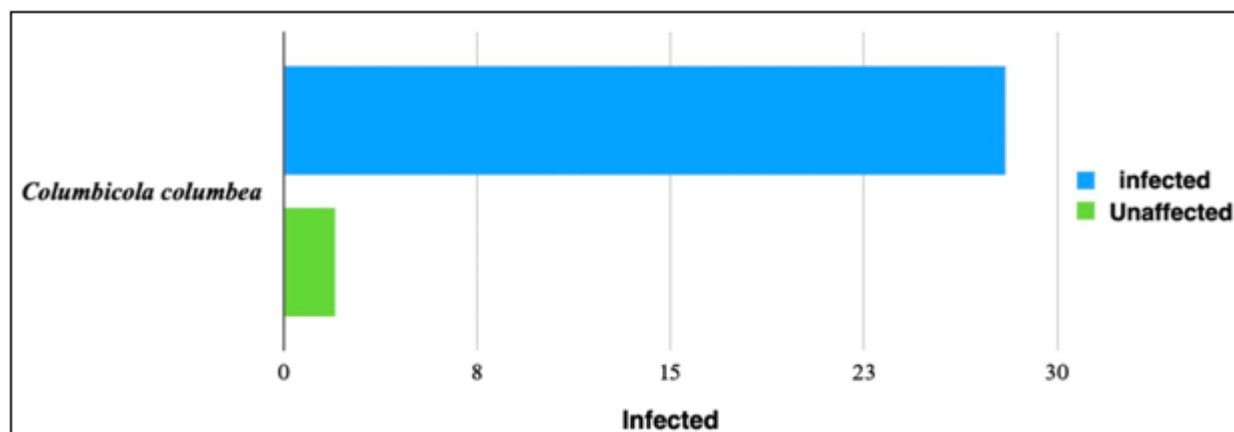


Figure 1: Comparison percentages of count lice (chewing lice) that infected pigeon

3.1 Classification of *C. columbae* (Table 2)

Kingdom: Animalia
Phylum: Arthropoda
Class: Insecta
Order: Phthiraptera
Suborder: Ischnocera
Family: Philopteridae

Genus: *Columbicola*

Species: *columbae*, Linnaeus, 1758 (Ansari 1947).

3.2 Key to the chewing lice species of *Columbia*

Table 2: Classification key Naz, et al., (2012)

1 Maxillary palpi present; meso and metathorax separate.....	Amblycera, 2
- Maxillary palpi absent; meso and metathorax fused, forming pteronotum	Ischnocera, 2
2 Head circumfasciate; temples large or broad, angulated	2
- Head non-circumfasciate; temples short and rounded	3
3 Median head setae blade-like, on anterior dorsal plate; anterior dorsal plate divided medially; preantennal width narrow	Columbicola, 4
4 Head length more than 0.55mm; posterior median head setae spike-like, shorter than anterior median head setae; male genitalia with triangular mesosomal plate, with groves directed towards median; female subgenital plate without a lateral row of setae, a groove with clear lateral indentations.....	5
5 Head length less than 0.55mm; posterior median head setae hair-like or spike-like, equal or longer than anterior median head setae; male genitalia with medially divided mesosomal plate, with anterior groove, bearing pores in or out of the pigmented border; female subgenital plate with a lateral row of setae, groove without indentation.....	6
6-Posterior median head; setae spike-like, more or less equally long to anterior median head setae; male genitalia with short, stumpy parameres, curved inside outwards, mesosomal plate with large or deep anterior groove, anterior pair of mesosomal pores present at lateral margins within the dark pigmented borders; female subgenital plate relatively wider with wavy posterior groove, long and wide, bearing 4–8 pairs of medium to long setae.....	C. columbae

3.3 Description

C. columbae are usually called slender chewing lice (Figure 2). This type of louse is considered a specialized parasite of

the pigeon family because pigeons are the host. Therefore, pigeon lice are denominated relative to the host that they parasitize.

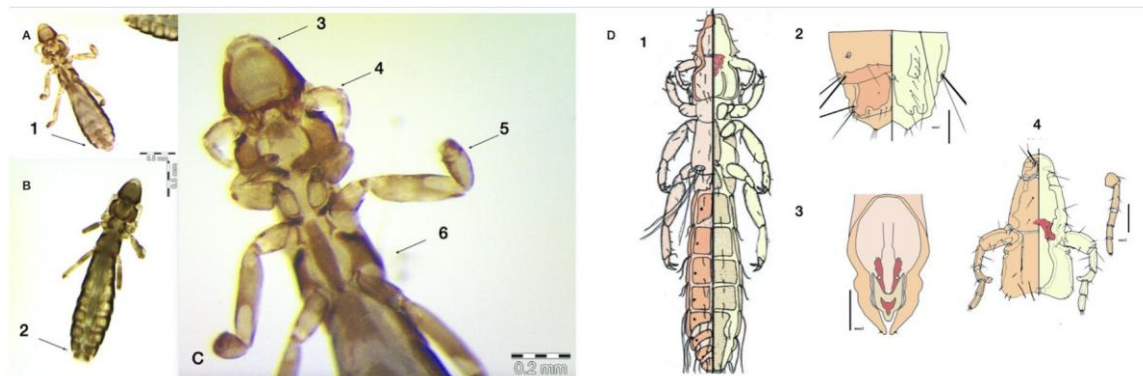


Figure 2 *C. columbae* by dissecting light microscope and Diagram .(A, B, C, D)A - The general form of a male of Mallophaga lice B - The general Morphology of a female of Mallophaga lice C - the front end of the body clarify the head and thorax area and legs. D-Diagram General shape and genital parts.

Abbreviation A, B, C: (1 - the end of male 2 - the end of female 3 - head 4 - the antenna sensor in the male 5 - the second appendages of legs 6 - thorax area) D-(1 - General shape of the dorsal and abdominal lice Mallophaga 2 - Genital organ in female 3 - Genital organs in male. 4-2 - capsule of the head in the female 3 - The diagram of the head in male and female.)

3.3.1 General Shape

The lice are characterized by long and slim bodies ranging from 2.00–2.2 mm in length in males and 2.4–2.7 mm in length in females. The head is usually oriented forward and long. The lice are brown in color. The antennae consist of five equally sized and similar segments in the female, as

shown by electron microscopy in Figure 3. Males and females are different in shape and size, as shown by electron microscopy in Figure 4. Chewing lice usually have long wing feathers, as shown in Figure 4.

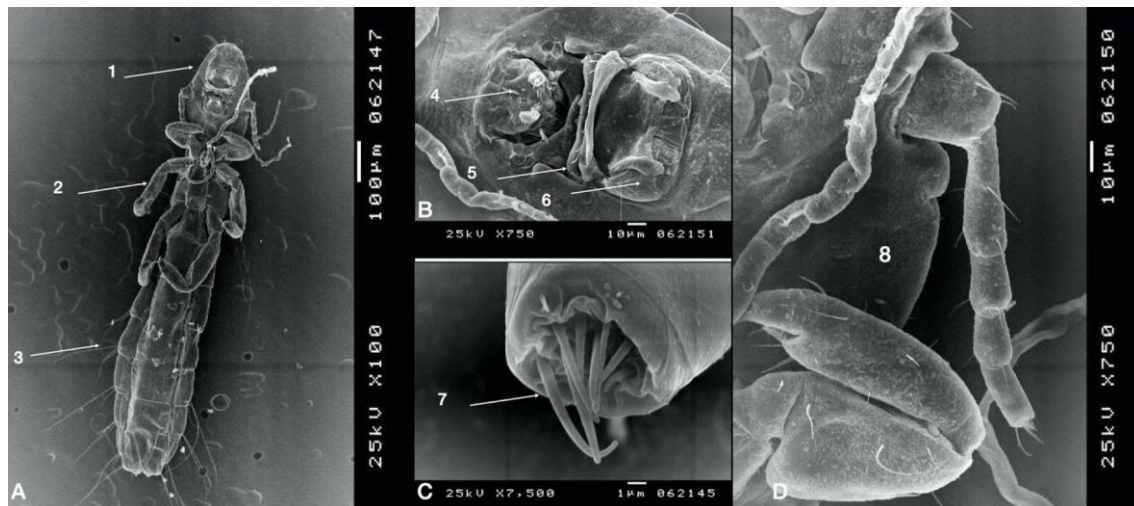


Figure 3: *C. columbae* by scanning electron microscope. (SEM). A. The abdominal area of the female shows a part of the body. B. The clarifies the shape of the mouthparts in the female and the shape of the head. C. The terminal end of the antenna, which is characterized by a number of sensory bristles (8 bristles) D. The general shape of the antenna sensor in females, which is characterized by four equal segments.

Abbreviation : 1 - head area 2 - thorax area 3 - abdominal area 4 - mouth cavity lingual sclerite 5 - Mandibles 6 - labrum 7 - the enlargement of sensory hairs at the end of the antenna sensor 8 - segments of the antenna in female its o to be equal and have bristles in terminal end

3.3.1.1 Head Area

In males, the head is elongated and large, as shown in **Figure 4**. It bears antennae, which consist of 4 segments, as shown by electron microscopy in **Figure 2**, but the segments are not equal in size. The second segment is rectangular. At the end of the third segment is an extension of the outer body. The fourth and fifth segments are equal and small in

size, as shown in **Figure 4**. At the ends of the antennae, there are sensory bristles that are characterized by different shapes and sizes (3 small and thick bristles equal in length and three long bristles with the same thickness), as shown in **Figure 4**.

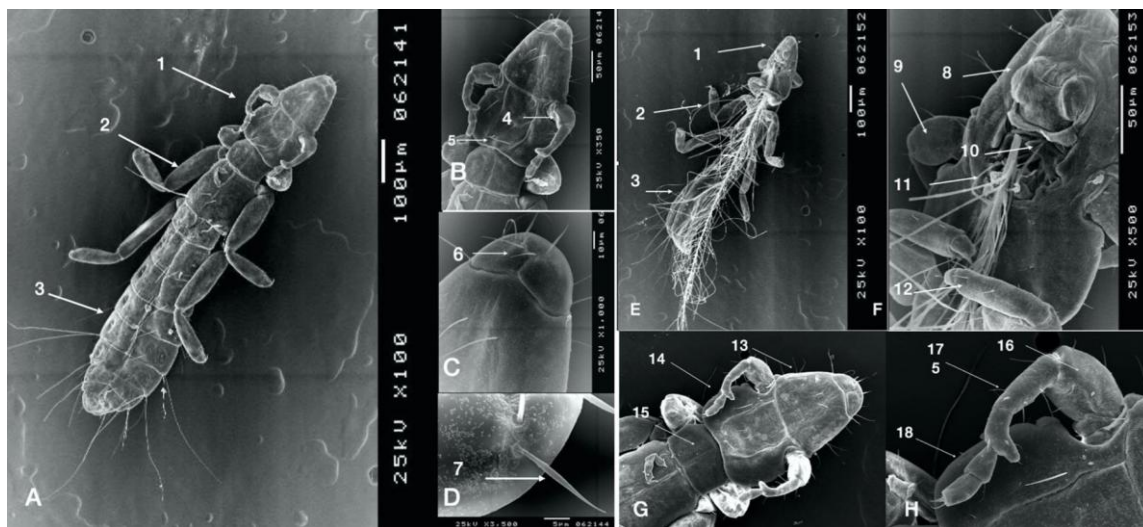


Figure 4: *C. columbae* by scanning electron microscope. (SEM). A. The general shape of the male from the dorsal view B. the front end of the head capsule clarify Shows the shape of the antennae in the male (characterized by segments different in size and shape to identify species. C. the front end and the distribution of bristles at the end of the front head capsule D. For the shape of the bristles in the head, which clarify the bristles distributed on three areas of the dorsal and abdominal and back. E. The general shape of the male abdominal area appears to be an attachment to the feather. F. Magnification of the front end clarifies the shape of the mouthparts and way of feeding during the catch the feathers. G. general shape of the male from the dorsal view and the front end of the head capsule clarify the shape of the antenna sensor in the male, whose segments are characterized by different sizes in size and shape with all the mind, a characteristic of the recognition of taxonomy between sex. Magnification of the antenna sensor in the male, which is characterized by four segments of unequal size. The first characterized as inflated, the next is smaller and bigger than the others from the end of the excess followed by the third and fourth pieces, which are small and similar in shape and ends with the last set of sensory filaments and identical with those found in female.

Abbreviation : (1 - head region 2 - thorax area 3 - abdominal area 4 - antenna sensor in the male 5 - head capsule 6 - the front end of the head capsule 7 - enlarge the shape of the bristles on the front of the head. 8- labrum 9 - the first segments of the antenna sensor in the male 10 - mouth 11 - mouth lingual sclerite 12 - the first pair appendages of of thorax during nutrition) 13- capsule of head 14- antenna sensor 15 - the first piece of thoracic from dorsal: 16- the first segments of the antenna sensor 17- the second segments 18- the third and fourth segments as similar and small.

Females appear to be more elongated and larger than males in general. However, the antenna segments are equal and small in size, as in males. The head bristles are divided into long, separated bristles, two at the top and two at the bottom, and are called 1- dorso-anterior head, 2- anterior medial head setae, and 3- posterior medial head, as shown in

Figures 2 and 5. Electron microscopy showed the same structures of oral parts in males and females, consisting of the upper lips, mandible, and mouth, as shown in **Figures 3 and 5.**

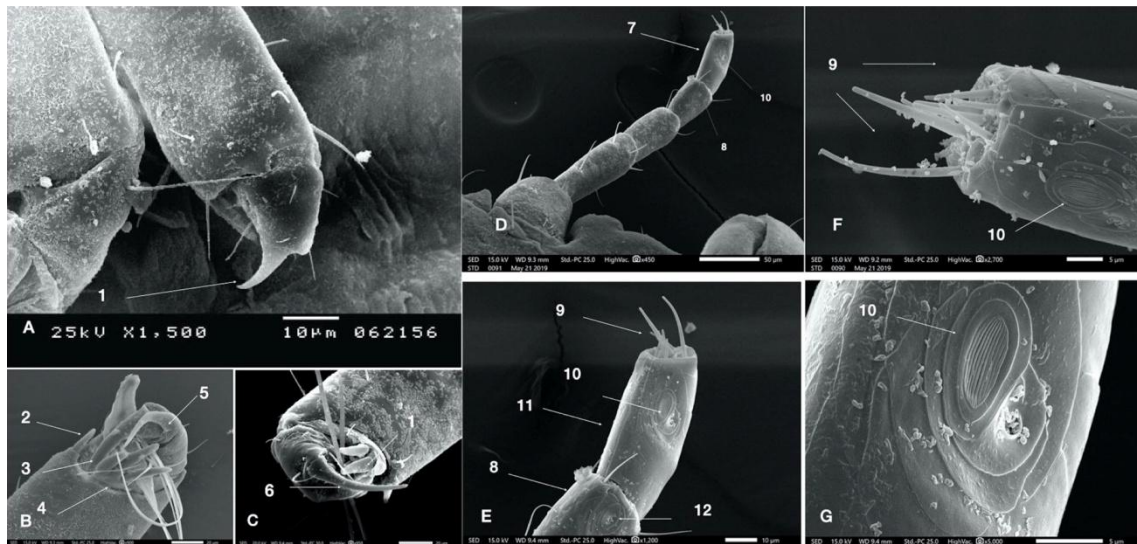


Figure 5: *C. columbae* by scanning electron microscope. (SEM). (A, B, C, D, E, F, G) A-The shape of end of the claws at first appendages of legs, which appears to be wide and has an end drawn but not significantly reversed B, C-enlarged of claws, which consists of two parts, one connected to the tarsus and wide and the other appears as part of the branch and smaller and thinner in the display as shown three separate spins separate It is as small as the thumb when it to gather like with each other pliers, D- general shape of antenna sensor in the female which consists of 4 equal segments and the shape of sensory bristles in the last terminal segments. E.end terminal for antenna sensor, which is characterized by a bristle. (8 bristles), two of which are longer than the other. F, G. Enlargement of the terminal segments, which clarify sensory organs and also the form of bristles.

Abbreviation : 1 - the first large claw 2 - the claw on the shape of the thumb 3 - the tip pulled from the large claw 4 - the claws in the form of thorns and have the same length 5 – the small claws view like branch from of the large 6 - the general shape of the large claw.7 - the terminal segments of antenna 8- the next segments of the terminal segment 9 - sensor y bristles in the antenna sensor 10 - sensory bristles in the antenna sensor 11 - the last segments of the antenna sensor 12 - sensory organ in the third segments of the antenna sensor.

3.3.1.2 Thorax Area

The thorax is composed of three integrated segments without any sections, but the three pairs of legs are similar in structure and different in direction. The first pair is oriented forward, and the rest are oriented in the opposite direction. Additionally, the first pair is smaller than the second and third pairs. The legs consist of a coxa trochanter femur tibia and tarsus, which are converted into two claws, as shown in **Figures 3 and 4.** The wrist is located on the last segment of the leg in the form of a small two-piece claw. The claw is characterized by different sizes: one is a large claw with a hidden end, and the other claw presents as a part of the other large claw, but it is smaller. At the base of the wrist, there are three wide and short thorns in addition to a small thorn-like thumb, as shown in **Figure 4.**

3.3.1.3 Abdominal Area

The abdomen is composed of nine segments in females and eight segments in males. The ninth segment is incorporated to form genitals in males. The abdomen is characterized by the presence of spiracles on each segment on each side in the pleural area, as shown in **Figure 6.** The posterior end of the female has two lobes, and at its end, there is a group of small bristles (2-3 bristles per branch), as shown in **Figures 3, 4, and 6.** In males, the genital organs are located at the end of the body and are characterized by having short borders that curve to the inside and the outside. These borders open towards the outside through a small opening on the abdominal side of the anus, as shown in **Figures 3, 4, and 6.**

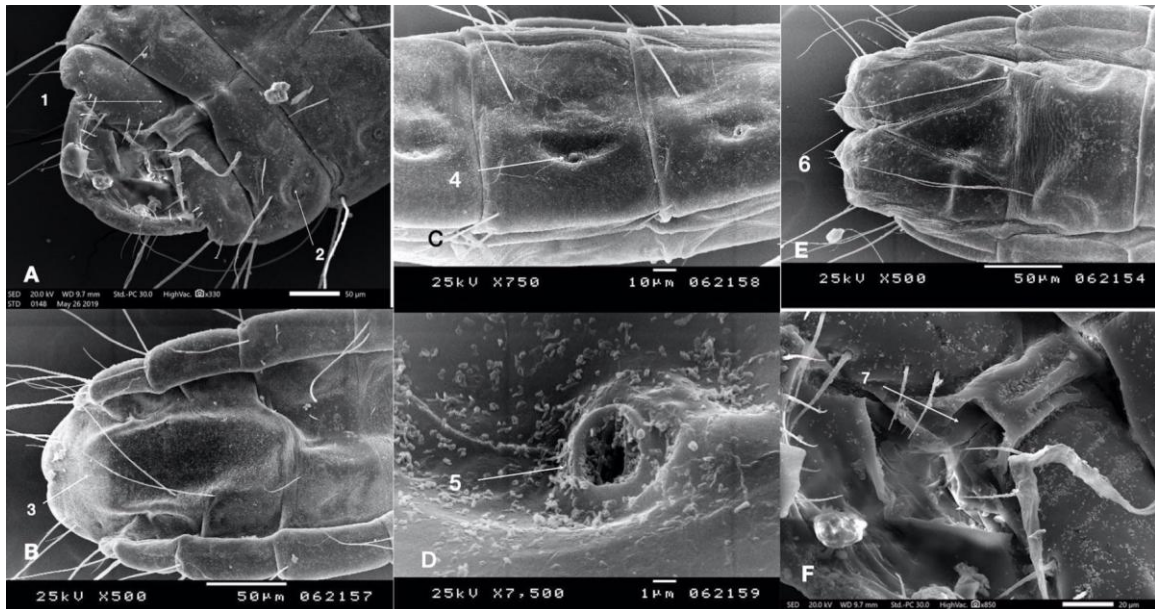


Figure 6: *C. columbae* by scanning electron microscope (SEM). A - the posterior end of the male abdominal B - a dorsal area of the end of the body of the male (genitalia) C- the spiracles located on the abdomen segments. D - enlargement of the spiracles opening in the abdomen segments. E- posterior end of the female B- terminal end of female F- enlarged view clarifies the anus opening in male

Abbreviations: (1- The opening of the genitals in the dorsal view in male 2, 4 - the spiracles opening on the sides of the abdominal segments 3-genital organs from terminal segments of abdomen 5 - enlarge the opening of the spiracles. 6- terminal end of female with two part and sensory 7-opening of anus)

4. Discussion

Birds are commonly infested by chewing lice because of their moving nature. They may also be affected through contact with other infected birds. This study recorded 38 infected birds out of 40 birds, confirming an infestation rate of nearly 95%. Chewing lice have spread throughout the world (Gibbs et al., 2001). Negligence by breeders in care and control can be considered reasons for this spread. *C. livia* infection with ectoparasites (*C. columbae*) was recorded in Saudi Arabia. This is consistent with the findings of Tuolah (1990) and Abdelmageed et al. (2018). A study surveying ectoparasites on poultry living in an open environment (Radfar et al., 2011) found that the birds were infested with *C. Columbae* at a rate of 41.30% when household pigeons were present in the same place. Harlin (1994) agreed that infestation with *C. Columbae* affects birds living in the same place. The outbreaks are likely to be similar to those in poultry and other birds (Hamad-Ameen and Al-Iraqi, 2007). Therefore, pigeon management programs should be implemented to reduce the risk of parasite transmission in a given region.

Tuolah (1990) recorded endoparasites and ectoparasites that affect pigeons and turkeys in Saudi Arabia. *C. columbae* was the most common louse on all birds.

Researchers have mentioned that it is also challenging to control pigeon nests, but it is not an epidemiological phenomenon. However, it is preferable to protect pigeons so that the breeder does not lose their birds in the event of a significant infestation. This is consistent with the report of Al-Shuaaibi (2008).

This study clarified that the distribution of sensory bristles at the ends of the antennae could be considered a diagnostic character among different genera and species (Ahmad et al., 2012, Naz et al., 2012), which proved that these features differ among genera and species. Thus, sensory bristle distribution is considered a diagnostic character (Smith, 2001).

5. Conclusion

Ectoparasites are most common in birds, especially pigeons, because these hosts move from one place to another. This study clarified the ultrastructure of *C. columbae*, which affects pigeons that live in Saudi Arabia, adding to the research on this species in the region. The results of this study also demonstrate the importance of determining the distribution of sensory bristles at the ends of the antennae, which is an important character for the identification and classification of species. This study is the first of its type in Saudi Arabia. The findings should be considered an indicator of diseases in the region and emphasize that it is necessary to develop a successful plan to prevent and control chewing lice.

References

- [1] Abdelmageed, E., Abdelgadir, M., Babiker, M. Y. A., and Al Rashidi, M. (2018). Survey of External parasites of House sparrows (*Passer domesticus*) in Hail Region, Saudi Arabia. *Adv. Biores.* **9**(1): 61-66.
- [2] Alahmed, A., Shobrak, M., Kheir, S., & Nasser, M. (2015). Little known chewing lice (Phthiraptera) infesting crab plover *Dromasardeola* Paykull, 1805

- (Charadriiformes: Dromadidae) from the Red Sea. *Acta tropica*, 150, 171-175.
- [3] Adams, R. J., Price, R. D., and Clayton, D. H. (2005). Taxonomic revision of OldWorld members of the feather louse genus *Columbicola* (Phthiraptera: Ischnocera), including descriptions of eight new species. *Journal of Natural History*, 39(41): 3545–3618
- [4] Adang, K.L., Oniye, S.J., Ezealor, A.U., Abdu, P.A. and Ajanusi, O.J. (2008). Ectoparasites of Domestic Pigeon (*Columba liviadomestica*, Linnaeus) in Zaria. *Nigeria Research Journal of Parasitology*, 3 (2): 79-84.
- [5] Ahmad, A., Arya, G., Bansal, N., Sychra, O., and Saxena, A. K. (2012). A note on phthirapteran ectoparasites infesting Yellow-legged Green Pigeon *Treronphoenicoptera* (Columbiformes: Columbidae). *Turk. J. Vet. Anim. Sci*, 36(6): 618-621.
- [6] Al-Shuaaibi, M.M. (2008). Study of prevalence haemoparasites in different birds from Al-Ramadi city. *Anbar Journal of Agricultural Sciences*, 6(2): 288-292.
- [7] Fatihu, M.Y., Ogbogu, V. C., Njoku, C.V., and Sarror, D.I. (1991). Comparative studies of gastrointestinal helminth of poultry in Zaria. *Rev Elev Med Vet Pays Trop*, 44(2):175-7.
- [8] Gibbs, D., Barnes, E., and Cox, J. (2001). Pigeons and doves: A guide to the pigeons and doves of the world. Yale University Press, New Haven, Connecticut.
- [9] Gustafsson D.R, Tsurumi, M., and Bush, S.E. (2015). The Chewing Lice (Insecta: Phthiraptera: Ischnocera: Amblycera) of Japanese Pigeons and Doves (Columbiformes) with Descriptions of Three New Species. *J Parasitol*, 101(3):304-13.
- [10] Hamad-Ameen, K.A., Al-Iraqi, R.A. (2007). Survey and Identification of lice species on chicken in Erbil governorate. *Iraqi J. Vet. Sci*, n/a(21) :13–21.
- [11] Harlin, R.W. (1994). Pigeons. *Veterinary Clin. North Am. Small Anim. Pract*, n/a (24):157–173.
- [12] Naz, S., Sychra, O., and Rizvi, S.A. (2012). New records and a new species of chewing lice (Phthiraptera, Amblycera, Ischnocera) found on Columbidae (Columbiformes) in Pakistan. *ZooKeys*, n/a (174): 79–93.
- [13] Nasser, M. G., Alahmed, A., & Shobrak, M. (2016). New host/parasite record for very rare chewing louse *Cuculotogaster arabicus* (Clay, 1938)(Phthiraptera: Ischnocera) on endemic mountain partridges of Arabian Peninsula. *Parasitology research*, 115(11), 4433-4436.
- [14] Nasser, M.G., Al-Ahmed, A., Ansari, M.J., Shobrak, M.Y., 2015b. Chewing lice (Phthiraptera) infesting breeding Suliformes (Aves: Aequornithes) of the Arabian Peninsula. *African Invertebrates* 56 (3), 709–717.
- [15] Piasecki, T. (2006). Evaluation of pigeon (*Columbia Livia-Urbana*). Health status in relation to their threat to human health. *Medycyna*, n/a(62): 531–537.
- [16] Price, R.D., Hellenthal, R.A., Palma, R.L., Johnson, K.P. and Clayton, D.H. (2003). The Chewing Lice: World Checklist and Biology Overview. Illinois Natural History Survey Special Publication 24. Illinois Natural History Survey, Illinois.
- [17] Radfar M.H., Fathi S., Asl E.N., Dehaghi M.M., Seghinsara H.R.A., (2011). Survey of parasites of domestic pigeons (*Columba livia domestica*) in South Khorasan. Iran. *Veterinary Research*, 4(1):18–23.
- [18] Sari, B., Karatepe, B., Karatepe, M. and Kara, M. (2008). Parasites of domestic pigeon (*Columba livia domestica*) and wild (*Columba livia Livia*) pigeons in Niğde. Turkey. *Bull Vet Inst Pulawy*, n/a (52): 551–554.
- [19] Singh, S.K., Arya, S. and Khan, V. (2010). Feeding and reproductive behavior of slender pigeon louse, *Columbicola columbae* (Phthiraptera, Insecta, Ischnocera). *Journal of Applied and Natural Science*, 2 (1): 126–133.
- [20] Smith, V. S. (2001). Vian louse phylogeny (Phthiraptera: Ischnocera): a cladistic study based on morphology. *Zoological Journal of the Linnean Society*, 132(1):81–144.
- [21] Soulsby, E. J. L. (1982). Helminthes, Arthropods, and Protozoa of Domesticated Animals. Billiere Tindall and Cassell Ltd., London.
- [22] Tahmasebi, P., Javadpour, F. and Sahimi, M. (2015). Three-Dimensional Stochastic Characterization of Shale SEM Images. *Transport in Porous Media*, 110. (3): 521-431.
- [23] Toulah F. H., (1990), Identification of external and internal parasites infesting domestic pigeon and turkey in Saudi Arabia .MSc Thesis, King Abdelaziz University. Jeddah, Saudi Arabia.
- [24] Turner, M.L., Baker, C., and Marais, R. (2002). Scanning electron microscopical investigation of the waterbuck louse *Bovicola* (syn. *Damalinea*) hills found at the Rietvlei. Nature Reserve near Pretoria Koedoe, n/a (45) :59–63.